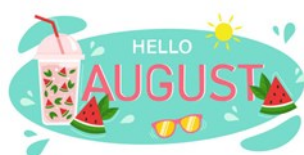

AUGUST 2024

SURGICAL GRAND ROUNDS



Inside this issue:

<i>Surgical Grand Rounds</i>	1-7
<i>Meet Our New Residents</i>	8-10
<i>Down Memory Lane</i>	11-12
<i>WSU Conferences</i>	13
<i>WSSS Dues</i>	14
<i>WSSS Members</i>	15-16



2023 WSSS OFFICERS

President:

Larry Narkiewicz (WSU/GS 2004/09)

Vice-President:

Joseph Sfera (WSUGS 1991)

Secretary-Treasurer:

Bruce McIntosh (WSU/GS 1989/94)

Members-at-Large:

Jay Dujon (WSUGS 2011)

Anita Antoniolu (WSUGS 1998)


Resident Member:

Paige Aiello

Molly Belisle

The Surgical Grand Rounds on Wednesday, 7/10/2024

was presented by Dr. Alyssa Stroud (WSUGS 2023) who is the Fellow in Minimally Invasive Surgery. She discussed the physiology and treatment of achalasia and reviewed the anatomy and physiology of the esophagus, noting that dysfunction of the lower esophageal sphincter (LES) occurs in about 1/100,000 people. The esophagus is approximately 25 cm in length, extending from the cricopharyngeus to the LES. The esophagus has no serosa but has two muscle layers, including an inner circular layer and an outer longitudinal layer. At the distal end of the esophagus is Auerbach's plexus which provides muscular control of the distal esophagus. There are three types of peristalsis with the primary peristaltic wave beginning at the cricopharyngeus and extending down the esophagus until it reaches the LES, which then relaxes and allows for the bolus to enter the proximal stomach which has simultaneous increased compliance. The secondary esophageal wave begins in the mid-esophagus and is an automatic wave which clears out any residual after the primary wave. The proximal half of the esophageal musculature is striated, whereas the distal half is smooth muscle which is where the automatic secondary esophageal wave begins. The third type of wave is the discordant wave. Acetylcholine facilitates contraction, whereas nitrous oxide inhibits contraction.



Dr. Alyssa Stroud

Patients with achalasia have histologic changes which may include inflammation, fibrosis, and replaced nerve cells in the lower plexus. Sometimes the achalasia may be due to a bacterial problem due to T. cruzi which is more common in South America, and there are potential genetic causes related to patients who have decreased adrenal function. The symptoms of achalasia commonly include dysphasia, heartburn, reflux, repeated cough, and weight loss. This entity is not curable but is treatable. Long-term achalasia may be associated with the development of lower esophageal cancer, so that when achalasia occurs in the senior citizen without a prior history, one should do careful ultrasound examination to be sure there is no small cancer causing the symptoms.

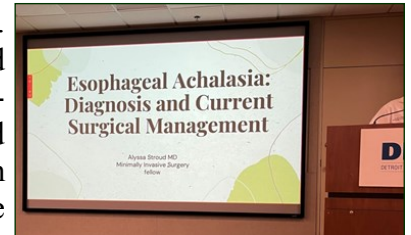
The score for evaluating the severity of achalasia includes the following features: Weight loss, pain, dysphasia, and regurgitation. Diagnosis is typically

Continue page 2

AUGUST 2024

SURGICAL GRAND ROUNDS

made by endoscopic examination with manometry being the gold standard. The barium swallow will typically show the distal narrowing, often described as a “bird’s beak.” The importance of measuring the upper esophageal sphincter (UES) as part of the total manometric examination was also described, and the integrated relaxation pressure (IRP) should not be greater than 15. This can be monitored approximately ten seconds following a swallow, and persistence of the IRP greater than 15 mmHg is diagnostic of achalasia.



Dr. Stroud described that calcium channel blockers, such as nifedipine, may alleviate symptoms of achalasia and noted the role of anticholinergic medicines and botulinum toxin effects on smooth and striated muscle.

Early non-invasive treatment of achalasia would include balloon dilation with a firm balloon dilating the distal esophagus where the narrowing is present. This is associated with fracture of the muscularis propria and may be repeated at 4-6 week intervals in order to eventually produce a good long-term result. One of the complications of this procedure is perforation so one has to assess for perforation when this procedure is performed. Also, the Heller myotomy is the gold standard for achalasia and yields excellent results more than 90% of the time. The myotomy should be started at the upper part of the esophagus which is narrowed, and then extended down onto the anterior musculature of the stomach through the so-called “rosette” where the gastric muscle fibers are angulated, and continue the incision down to the point where the gastric muscle fibers are transverse. One of the complications of the Heller myotomy, whether done open or laparoscopically, is perforation. This may be treated by primary closure, followed by a Dor fundoplication, which is essentially a procedure by which the fundus is mobilized in order to be tacked over the area of the myotomy which would include the perforation which has been closed. Perforation occurs in about 8-15% in reported series of patients having the Heller myotomy.

Some of the differences between the laparoscopic vs. the robotic Heller myotomy basically include increased time, decreased length of stay, and similar long-term results.

The Peroral endoscopic myotomy (POEM) is not being done currently at WSU but because of the good results that are being reported with POEM, Dr. Stroud plans to introduce that procedure to WSU during her Fellowship year. There was an active question-and-answer session after the presentation.



Continue page 3



AUGUST 2024

SURGICAL GRAND ROUNDS

Dr. Robert Joslin, from the DMC Department of Anesthesiology, presented at the WSU Department of Surgery **Grand Rounds on 7/17/2024**. His talk was entitled “Trauma Anesthesia and Perioperative Volume Resuscitation.”

Trauma continues to be the number one cause of death in America, and anesthesia plays a very important part in early resuscitation, both in the Emergency Department and in the operating room. Many of these injuries occur during off hours, and often there are occult injuries not readily recognized on the first examination.



Dr. David Edelman (WSU/GS 2002/09) introduces Dr. Robert Joslin

The principles of ATLS were discussed as part of the primary and secondary evaluations in the Emergency Department and in the operating room. Many of these patients (7% to 30%) require an urgent airway. One of the factors in establishing an early airway is to look for any impediments. One can learn a lot by talking to the patient if the patient is conversant or, if the patient is unconscious, by chest auscultation in order to determine whether there is any underlying unsuspected pneumothorax or hemothorax. He emphasized the value of ultrasound in facilitating this examination. Things that might interfere with establishing an early airway might include a cervical collar, pharyngeal bleeding, or a foreign body. Monitoring the distance from the chin to the thyroid is very helpful, and one should also be thinking of a foreign body of false teeth or dentures. He explained the classifications for evaluating the potential difficulties before attempting an emergency airway.

The different techniques that can be used to examine the airway in order to get successful intubation were discussed, including direct laryngoscopic examination, video-assisted examination, fiber optic visualization, the LMA, and the blind nasal intubation. Each of these techniques has a place depending on the circumstances. When the above cannot be successfully used for intubation, some type of surgical airway is indicated, which might include the cricothyroidotomy.

Different medications may be used to establish the emergency airway. These might include Etomidate, ketamine, succinylcholine, or some of the longer acting drugs. It is also important to check for CO₂ return to ensure that the intubation has been successful.

Some of the problems that can be identified when there is airway injury were described, as well as how this can interfere with successful intubation. Once the intubation is successfully accomplished, he recommended that the tidal volume be 6-8 ml/Kg and the respiratory rate be initiated at 12-14/min. He also recommended positive end expiratory pressure of 5 and that peak airway pressure be kept under 35 mmHg.

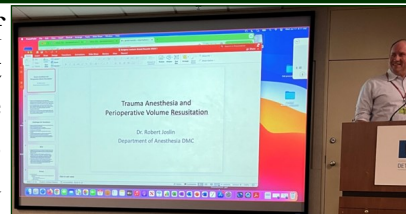
Continue page 4



AUGUST 2024

SURGICAL GRAND ROUNDS

The importance of re-establishing circulation with a balanced regimen of crystalloids, blood, and plasma was noted. When patients have significant bleeding, the first finding is tachycardia, which is associated with protective vasoconstriction, oliguria, and hypotension which occur when the patient is severely under resuscitated. The importance of following pulse rate and pulse pressure was emphasized, and the importance of Poiseuille's Law as it relates to pressure was also highlighted.



Besides standard intravenous lines for establishing circulation, intra-osseous lines allow for rapid intravenous fluids to be administered when the more commonly used IV sites are compromised. This may be seen in patients who are drug users.

The triad of death was emphasized, which includes coagulopathy, acidosis, and hypothermia. Also discussed were the guidelines for following ongoing resuscitation which are similar to those described in the Surviving Sepsis Campaign literature.

Patients with associated traumatic brain injury should be resuscitated in order to establish cerebral perfusion pressure (CPP) of greater than 50 mmHg, and he described the role of hypertonic saline and Mannitol in order to try to reduce the elevated intracerebral pressure. Finally, some of the different techniques for reversing anti-coagulation in patients who arrive on some type of anti-coagulation were discussed. There was an active discussion session following the presentation.



The WSU Department of Surgery **Grand Rounds on 7/24/2024** was presented by Dr. Kenton Zehr, entitled "A Brief History of Cardiac Surgery." Dr. Zehr described how the first heart transplant was performed in 1967 by Dr. Christiaan Barnard at the Groote Schuur Hospital in Cape Town, South Africa. The patient lived 18 days. Dr. Barnard had previously spent time at the University of Minnesota working with Dr. C. Walton Lillehei who did the first open heart operation in 1952. Dr. Lillehei was one of the great pioneers in heart circulation and was the individual who mastered cross circulation during heart operations and was also the individual who developed the pacemaker. Dr. Lillehei was a very busy open heart surgeon throughout his time at the University of Minnesota and also when he left Minnesota for the eastern part of this great nation.



Dr. Kenton J. Zehr

Continue page 5



AUGUST 2024

SURGICAL GRAND ROUNDS

The second heart transplantation was performed by Dr. Adrian Kantrowitz at the Mainonides Hospital in Brooklyn, New York. This was the first heart transplantation done on a child who was 18 days old. The recipient was born with the Ebstein anomaly, and the donor was a newborn with anencephalism who died six hours after birth. Dr. Kantrowitz later moved to the Sinai Hospital in Detroit and more than once was a speaker at the WSU Grand Rounds.

Early experimentation with heart transplantation had begun in canine models more than 100 years ago. Drs. Alexis Carrel and Charles Guthrie at the University of Chicago performed canine cardiac transplantations. These transplantations resulted in early death for a number of reasons. Dr. Norman Shumway, a native Michigianian, along with his colleague, Dr. Richard Lower, were pioneers in cardiac transplantation at Stanford University. During his early years, Dr. Shumway was at the University of Minnesota and was part of the team that worked with Dr. Lillehei. Dr. Shumway and his team studied the major impediments to successful cardiac surgery which included the lack of appropriate control of the immune system and maintenance of good perfusion in the donor heart prior to transplantation. The pioneering work done by these two individuals was, to a large extent, responsible for the later successes in this field. Dr. Shumway performed his first cardiac transplantation at Stanford in 1968.

The frequency of heart transplantation mushroomed so that by the end of 1968, there had been 102 cardiac transplantations performed in 17 different countries at 52 different cardiac centers. Dr. Denton Cooley performed the first implantation of an artificial heart, but the patient survived only two days. Because of the uniform bad results with cardiac transplantation, the number of centers continuing to perform this procedure by 1970 had decreased to Dr. Shumway at Stanford, Dr. Lower who had now moved from Stanford to Virginia, Dr. Marcus Barnard (Christiaan's younger brother in Cape Town), and Dr. Christian Cabrol-La Pitie in Paris.

The great advance in cardiac transplantation occurred when the concept of "brain death" was defined as total body death so that patients with a beating heart could become donors for cardiac transplantation, and the effectiveness in the immune therapy to prevent rejection was perfected. One of the major advances in this area was the development of cyclosporine which demonstrated its great effects in kidney transplantation and then became routinely used for cardiac transplantation.

The WSU Department of Surgery became involved in open heart surgery when Dr. Alan Thal became the Chairman of the Department of Surgery and brought with him Dr. Raymond Read who was the first assistant at Minnesota for Dr. C. Walton Lillehei. WSU never became involved at this time in cardiac transplantation.

Continue page 6

AUGUST 2024

SURGICAL GRAND ROUNDS

The field of heart transplantation has grown tremendously. Currently, more than 3,000 heart transplantations, including more than 500 in children, are being done yearly. The results have improved tremendously so that over 90% of recipients are living at one year, and over 80% of recipients are living at five years.

Following his presentation, there was a good question-and-answer session.



The **Surgical Grand Rounds on Wednesday, 7/31/2024**, was presented by Dr. Brandi Miller, the Chief of Urology at the Detroit Receiving Hospital. The title of her talk was, “Difficult Foley Catheterizations and Urethral Trauma.” Dr. Miller emphasized the importance of getting a history when placing a Foley in order to anticipate when there may be problems with insertion. Most of the time, the so-called difficult Foley catheter insertion is “not difficult” when someone with more expertise is called to provide help. There are different types of catheters, including the coude, the three-way catheter for patients with hematuria, and the silicone catheter. The catheters are categorized by size according to the French nomenclature, and this is color coded so that the commonly used yellow Foley catheter is a French 20 size. The different types of injury to the urethra were discussed, including both the anterior and posterior urethra. One of the causes of injury is to inflate the Foley balloon within the urethra, so one has to be careful to be sure that the balloon is already in the bladder before any inflation is performed. Other causes of difficult insertion include meatal stenosis, phimosis, prostatic enlargement, and creation of a false passage. When there is question or difficulty with insertion of a catheter, cystoscopy can provide guidance with placement of a guide wire in the bladder or the performance of a suprapubic tube catheter when all other efforts fail.



Dr. Brandi Miller

There can sometimes be malfunction of a Foley catheter which can be due to the fact that there may be a faulty valve within the catheter or the channel of the catheter is actually blocked due to blood clot or some other substance. Sometimes there is calcium formation on the catheter when the catheter has been in for some time. Usually when the catheter doesn't come out, there is some residual fluid within the Foley catheter balloon. Cutting the Foley catheter in half allows for all of the fluid within the balloon to be evacuated, and the catheter can then be removed. Common causes of anterior urethral trauma were discussed, including penetrating wounds, iatrogenic injury, and blunt trauma, particularly involving serious injury to the pelvis or pubis. She classified the severity of injury as 1) contusion; 2) stretch injury or

Continue page 7

AUGUST 2024

SURGICAL GRAND ROUNDS

elongation; 3) partial rupture; 4) complete rupture, and 5) complete rupture with more than 2 cm separation from the urethra and bladder neck. There can also be rupture into the vagina or into the prostate gland. The Goldman classifications for urethral injury were also discussed, which have some modifications from the above classifications.

The role of a retrograde urethrogram (RUG) when working up a patient who has a potential rupture of the urethra was discussed. Indications for the RUG would include blood on the meatus, penile hematoma, and labial or perineal hematoma. Occasionally, a CT scan or MRI may be helpful in identifying the relationship of the urethra to the surrounding structures. Patients with pubic fracture and pubic separation have an increasing incidence of urethral rupture for every 1 mm of pubic symphysis separation.

Injuries to the anterior urethra are often related to penetrating wounds and do well with early primary repair. This is followed up by having an in-dwelling Foley catheter present for one or two weeks in order to protect the repair from any lateral pressure. The repair is typically done in an end-to-end manner, but there is a significant post repair stricture which in some reports goes up to 25%. She also described the importance of early replantation in patients who have amputation of the penis. When that is not possible, the patient would be treated with a perineal urethrostomy.


The different grades of injury for the posterior urethra were also discussed. This includes 1) stretching; 2) stretching with injury to the urogenital diaphragm (UGD); 3) anterior posterior injury involving the UGD; 4) combined bladder neck and urethral involvement; and 5) complete anterior disruption. Primary repair of combined bladder neck and urethral injuries is best done early, which may be immediately or extend up to six weeks. A suprapubic tube is routinely used in view of the high incidence of stricture formation, and when stricture formation occurs, the definitive repair should be done more than three months after injury.



AUGUST 2024

MEET OUR NEW RESIDENTS

This residency year, we have 17 PGY-1 residents in the Detroit Medical Center/Wayne State University Program in Surgery who have joined us in July. Let's welcome them with open arms when we see them in the halls of the Detroit Medical Center. The New Faces for 2024-2025 are listed below:



Dr. Suma Alzouhayli comes to us from our Wayne State University School of Medicine. She is very interested in General Surgery.




Dr. Esther Bae is also another one of our Wayne State University School of Medicine graduates and is very interested in Anesthesia.



Dr. Danielle Barnes hails from the University of Toledo College of Medicine and Life Sciences and has a desire to know more about Orthopaedics.



Dr. Marilee Clunk also hails from the University of Toledo College of Medicine and Life Sciences and is interested in Orthopaedics.



Dr. Timothy Gilbert arrives at our program from the University of Michigan Medical School.




Dr. Veda Gokula also comes to us from the University of Toledo College of Medicine and Life Sciences program.

Continue page 8

AUGUST 2024

MEET OUR NEW RESIDENTS



Dr. Aranice Lassale hails from the University of Medicine and Health Sciences St. Kitts and is interested in Orthopaedics.



Dr. Drew Gryczewski is from the University of Toledo College of Medicine and Life Sciences and has an interest in Orthopaedics as well.



Dr. Kenzie Kao comes to us from the Saba University School of Medicine and would like to learn more about General Surgery.



Dr. Mohamen Khairalseed is from the Omdurman Islamic University Faculty of Medicine and Health Sciences and is interested in Radiology.



Dr. Kayla Martinez hails from the Ross University School of Medicine.



Dr. Muhammad Mehraiz comes to us from the Services Institute of Medical Sciences Pakistan and is interested in Radiology.

Continue page 9



AUGUST 2024

MEET OUR NEW RESIDENTS



Dr. J.D. Okuro comes to us from Saint James School of Medicine Anguilla.



Dr. Adam Olszewski is from our own Wayne State University School of Medicine.



Dr. Bianca Parker is also from our Wayne State University School of Medicine and is interested in Orthopaedics.



Dr. Katherine Schaub hails to us from the University of Toledo College of Medicine and Life Sciences.



Dr. Anna Vanderschaegen is from the Western Michigan University Homer Stryker MD School of Medicine.



EXCERPTS FROM THE LOG BOOK DOWN MEMORY LANE

4/15/72—Staff: Dr. C. Lucas; Chief Resident: Dr. A. Ledgerwood

1. RS: Mycotic aneurysm proximal carotid artery following GSW, treated with ligation proximal carotid artery and evacuation of clots.
2. JR: GSW abdomen with two holes in rectum which were closed and ten holes small bowel, treated with resection and closure of four holes primarily, loop sigmoid colostomy.
3. TW: Partial amputation fifth finger, repaired.
4. JL: Stab abdomen, laparotomy with closure one hole transverse colon.



Dr. Anna Ledgerwood

4/16/72—Staff: Dr. R. Krome

1. MO: Blunt trauma from MVC with laceration left lobe of liver; wound was sutured with cholecystostomy for liver study.

4/17/72—Staff: Dr. T. Flake

1. WB: 29 yo with stab abdomen; serosal tear small bowel which was closed.

4/18/72—Staff: Dr. C. Bernys

1. DW: 60 yo with blunt injury and fracture left ribs x5 and left hemopneumothorax and right ribs x3, treated with insertion of left chest tube.
2. YK: Abscess left neck in heroin user, treated with I&D abscess.
3. CN: Perforated duodenal ulcer with 2 liters of pus in peritoneal cavity, treated with Graham patch and irrigation.

Continue page 12



"EXCERPTS FROM LOG BOOK" - DOWN MEMORY LANE, cont...

4/19/72—Staff: Dr. J. Bassett

1. DL: GSW abdomen with three holes transverse colon, resected with end-to-end anastomosis and exteriorized anastomosis following protocol for randomized study.

4/20/72—Staff: Dr. Pelok

1. CN: Tracheostomy in patient with perforated duodenal ulcer.
2. WM: Shotgun wound right anterior chest wall and axilla with ten holes axillary artery and six holes axillary vein, treated with ligation of vein and resection of artery with end-to-end anastomosis; shotgun wound forehead and left eye, treated with debridement (left eye will probably need enucleation).

4/21/72—Staff:

1. WS: Tracheostomy for patient with hemorrhagic pancreatitis.
2. TP: GSW abdomen, treated with exploratory laparotomy with findings of thru-and-thru liver portal triad, aorta, vena cava, and hilum of right kidney, treated with repair of the cava and aorta. This patient expired in O.R. after 17 units of blood; patient had left thoracotomy in E.R.
3. JR: SW abdomen involving liver, small bowel, sigmoid and transverse colon, treated with colostomy, mucous fistula, and repair of holes in small bowel and suture of liver wound.
4. ML: GSW abdomen, treated with exploratory laparotomy and closure two holes small bowel and two holes urinary bladder and placement of suprapubic tube.
5. MW: Repair of flexor tendons to index finger.
6. HH: Stab of abdomen, treated with laparotomy and repair of diaphragm.
7. AW: Stab left neck with negative exploration of neck.



WSU MONTLY CONFERENCES 2024

Death & Complications Conference
Every Wednesday from 7-8



Didactic Lectures — 8 am
Kresge Auditorium

The weblink for the New WebEx Room:
<https://davidedelman.my.webex.com/meet/dedelman>

Wednesday, August 7

Death & Complications Conference

Dr. Yevgeniy Rits, MD

DMC/WSU School of Medicine

Wednesday, August 14

Death & Complications Conference

“Intestinal Transplant”

Dr. Shunji Nagai, MD, PhD

Surgical Director, Intestinal Transplant and Rehabilitation Program

Division of Transplant and Hepatobiliary Surgery

Henry Ford Hospital/Transplant Institute

Wednesday, August 21

Death & Complications Conference

Dr. Rupen Shah, MD

DMC/WSU School of Medicine

Wednesday, August 28

Death & Complications Conference

Dr. Ira Seth Winer, MD, PhD

DMC/WSU School of Medicine

KRESGE AUDITORIUM – SECOND FLOOR WEBBER BLDG

HARPER UNIVERSITY HOSPITAL, 3990 JOHN R.

7:00 Conference: Approved for 1 Hour – Category 1 Credit

8:00 Conference: Approved for 1 Hour – Category 1 Credit

For further information call (313) 993-2745

The Wayne State University School of Medicine is accredited by the Accreditation Council for Continuing Medical Education to provide continuing medical education for physicians. The Wayne State University School of Medicine designates this live activity for a maximum of 2 hours **AMA PRA Category 1 Credit(s)**[™]. Physicians should claim only the credit commensurate with the extent of their participation in the activity.”

EVALUATIONS

Surgical Death and Complications Rounds #2024321125, Jan-April 2024 CME Reflective Evaluation:

<https://www.surveymonkey.com/r/MJMNYV>

Surgery Grand Rounds #2024321064, Jan-April 2024 CME Reflective Evaluation:

<https://www.surveymonkey.com/r/MJW2XF>



Wayne State Surgical Society 2024 Donation

Name: _____

Address: _____

City/State/Zip: _____

Service Description	Amount
---------------------	--------

2024 Dues Payment _____	\$200 _____
-------------------------	-------------

My contribution for "An Operation A Year for WSU" _____	
---	--

*Charter Life Member _____	\$1000 _____
----------------------------	--------------

Total Paid _____

Payment by Credit Card

Include your credit card information below and mail it or fax it to
313-993-7729.

Credit Card Number: _____

Type: MasterCard Visa Expiration Date: (MM/YY) _____ Code _____

Name as it appears on card: _____

Signature: _____

Billing address of card (if different from above):

Street Address _____

City _____ State _____ Zip Code _____

*I want to commit to becoming a charter life member with payment of \$1000
per year for the next ten (10) years.

Send check made payable to **Wayne State Surgical Society** to:

Charles Lucas, MD
Department of Surgery
Detroit Receiving Hospital, Room 2V
4201 St. Antoine Street
Detroit, Michigan 48201

MARK YOUR CALENDARS

*Midwest Surgical Association Annual Meeting**August 4-6, 2024**Grand Hotel**Mackinac Island, Michigan*

*83rd Annual Meeting of the American Association for
the Surgery of Trauma/Clinical Congress of Acute
Care Surgery*

*September 11-24, 2024**Las Vegas, Nevada*

*American College of Surgeons Clinical Congress
Annual Meeting*

*October 19-22, 2024**San Francisco, California**72nd Annual Detroit Trauma Symposium**November 7-8, 2024**Detroit, Michigan*

Please Update Your Information

The WSUSOM Department of Sur-
gery wants to stay in touch.
Please email Charles Lucas at
clucas@med.wayne.edu to update
your contact information.



Missing Emails

Over the years the WSU Department of Surgery has lost touch with many of its alumni. If you know the email, address, or phone number of the following WSU Department of Surgery Residency Program graduates please email us at clucas@med.wayne.edu with their information so that we can get them on the distribution list for the WSU Department of Surgery Alumni Monthly Email Report.

Mohammad Ali (1973)

David B. Allen (1992)

Tayful R. Ayalp (1979)

Juan C. Aletta (1982)

Kuan-Cheng Chen (1976)

Elizabeth Colaiuta (2001)

Fernando I. Colon (1991)

David Davis (1984)

Teoman Demir (1996)

Judy A. Emanuele (1997)

Lawrence J. Goldstein (1993)

Raghuram Gorti (2002)

Karin Haji (1973)

Morteza Hariri (1970)

Harrison, Vincent L. (2009)

Abdul A. Hassan (1971)

Rose L. Jumah (2006)

R. Kambhampati (2003)

Aftab Khan (1973)

Samuel D. Lyons (1988)

Dean R. Marson (1997)

Syed A. Mehmood (2007)

Toby Meltzer (1987)

Roberto Mendez (1997)

Mark D. Morasch (1998)

Daniel J. Olson (1993)

David Packer (1998)

Y. Park (1972)

Bhavik G. Patel (2004)

Ami Raafat (1998)

Kevin Radecki (2001)

Sudarshan R. Reddy (1984)

Renato G. Ruggiero (1994)

Parvid Sadjadi (1971)

Samson P. Samuel (1996)

Knavery D. Scaff (2003)

Steven C. Schueller (1974)

Anand G. Shah (2005)

Anil Shetty (2008)

Chanderdeep Singh (2002)

David G. Tse (1997)

Christopher N. Vashi (2007)

Larry A. Wolk (1984)

Peter Y. Wong (2002)

Shane Yamane (2005)


Chungie Yang (2005)

Hossein A. Yazdy (1970)

Lawrence S. Zachary (1985)

Wayne State Surgical Society

The Wayne State Surgical Society (WSSS) was established during the tenure of Dr. Alexander J. Walt as the Chairman of the Department of Surgery. WSSS was designed to create closer contact between the current faculty and residents with the former resident members in order to create a living family of all of the WSU Department of Surgery. The WSSS also supports department activities. Charter/Life Membership in the WSSS is attained by a donation of \$1,000 per year for ten years or \$10,000 prior to ten years. Annual membership is attained by a donation of \$200 per year. WSSS supports a visiting lecturer each fall and co-sponsors the annual reception of the department at the annual meeting of the American College of Surgeons. Dr. Scott Davidson (WSU/GS 1990/96) passed the baton of presidency to Dr. Larry Narkiewicz (WSU/GS 2004/09) at the WSSS gathering during the American College of Surgeons meeting in October 2022. Members of the WSSS are listed on the next page. Dr. Narkiewicz continues in the hope that all former residents will become lifetime members of the WSSS and participate in the annual sponsored lectureship and the annual reunion at the American College of Surgeons meeting.



Ahn, Dean	Clink, Douglas	Gerrick Stanley	Lucas, Charles E.	Ramnauth, Subhash	vonBerg, Vollrad J. (Deceased)
Albaran, Renato G	Chmielewski, Gary W.	Grifka Thomas J. (Deceased 2022)	Malian, Michael S.	Rector, Frederick	Washington, Bruce C.
Allaben, Robert D. (Deceased)	Colon, Fernando I.	Gutowski, Tomasz D.	Marquez, JoFrances	Rose, Alexander	Walt, Alexander (Deceased)
Ames, Elliot L.	Conway, William Charles	Herman, Mark A.	Martin, Donald J., Jr.	Rosenberg, Jerry C.	Weaver, Donald
Amirikia, Kathryn C.	Davidson, Scott B.	Hinshaw, Keith A.	Maxwell, Nicholas	Sankaran, Surya	Whittle, Thomas J.
Anslow, Richard D.	Dente, Christopher	Holmes, Robert J.	McGuire, Timothy	Sarin, Susan	Williams, Mallory
Antonioli, Anita L.	Dujon, Jay	Huebl, Herbert C.	McIntosh, Bruce	Sferra, Joseph	Wills, Hale
Auer, George	Edelman, David A.	Johnson, Jeffrey R.	Missavage, Anne	Shapiro, Brian	Wilson, Robert F.
Babel, James B.	Engwall, Sandra	Johnson, Pamela D.	Montenegro, Carlos E.	Silbergleit, Allen (Deceased)	Wood, Michael H.
Bassett, Joseph (Deceased)	Francis, Wesley	Kline, Gary	Narkiewicz, Lawrence	Smith, Daniel	Zahriya, Karim
Baylor, Alfred	Flynn, Lisa M.	Kovalik, Simon G.	Nicholas, Jeffrey M.	Smith, Randall W.	
Bouwman, David	Fromm, Stefan H.	Lange, William (Deceased)	Novakovic, Rachel L.	Stassinopoulos, Jerry	
Bradley, Jennifer	Fromm, David G	Lau, David	Perrone, Erin	Sullivan, Daniel M.	
Busuito, Christina	Galpin, Peter A.	Ledgerwood, Anna M.	Porter, Donald	Sugawa, Choichi	
Crocco, William C.	Gayer, Christopher P.	Lim, John J.	Prendergast, Michael	Tuma, Martin	



Members of the Wayne State Surgical Society—2023-24 Dues

Alpendre, Cristiano V.	Goltz, Christopher J.	Marquez, JoFrances	Siegel, Thomas S.
Bambach, Gregory A.	Gutowski, Tomasz	Martin, Jonathon	Tarras, Samantha
Carlin, Arthur	Hall, Jeffrey	McGee, Jessica D.	Taylor, Michael G.
Chmielewski, Gary	Hollenbeck, Andrew	Mostafa, Gamal	Tennenberg, Steven
Dawson, Konrad L.	Joseph, Anthony	Nevonen, Marvin G.	Thoms, Norman W.
Dolman, Heather	Klein, Michael D.	Paley, Daniel S.	Vasquez, Julio
Dulchavsky, Scott A.	Kline, Gary	Park, David	Ziegler, Daniel W.
Fernandez-Gerena, Jose	Kosir, Mary Ann	Porterfield, Lee	
Field, Erin	Lloyd, Larry	Shanti, Christina	



Operation-A-Year January 1—December 31, 2024



The WSU department of Surgery has instituted a new group of alumni who are remembering their training by donating the proceeds of one operation a year to the department. Those who join this new effort will be recognized herein as annual contributors. We hope that all of you will remember the department by donating one operation, regardless of difficulty or reimbursement, to the department to help train your replacements. Please send your donation to the Wayne State Surgical Society in care of Dr. Charles E. Lucas at Detroit Receiving Hospital, 4201 St. Antoine Street (Room 2V), Detroit, MI, 48201.

Albaran, Renato G.	Dittinbir, Mark	Holmes, Robert J.	McGuire, Timothy	Sullivan, Daniel M.
Antonioli, Anita L.	Engwall, Sandra	Johnson, Jeffrey R.	McIntosh, Bruce	Wood, Michael H.
Bambach, Gregory A.	Fernandez-Gerena, Jose	Johnson, Pamela D.	Porter, Donald	Ziegler, Daniel
Bradley, Jennifer	Gutowski, Tomasz	Joseph, Anthony	Prendergast, Michael	
Busuito, Christina	Gayer, Christopher P.	Lim, John J.	Siegel, Thomas S.	
Chmielewski, Gary W.	Herman, Mark A.	Malian, Michael	Smith, Daniel	
Dente, Christopher	Hinshaw, Keith A.	Marquez, JoFrances	Smith, Randall	



WSU SOM ENDOWMENT

The Wayne State University School of Medicine provides an opportunity for alumni to create endowments in support of their institution and also support the WSSS. For example, if Dr. John Smith wished to create the "Dr. John Smith Endowment Fund", he could donate \$25,000 to the WSU SOM and those funds would be left untouched but, by their present, help with attracting other donations. The interest at the rate of 4% per year (\$1000) could be directed to the WSSS on an annual basis to help the WSSS continue its commitment to improving the education of surgical residents. Anyone who desires to have this type of named endowment established with the interest of that endowment supporting the WSSS should contact Ms. Lori Robitaille at the WSU SOM> She can be reached by email at lrobitai@med.wayne.edu.