



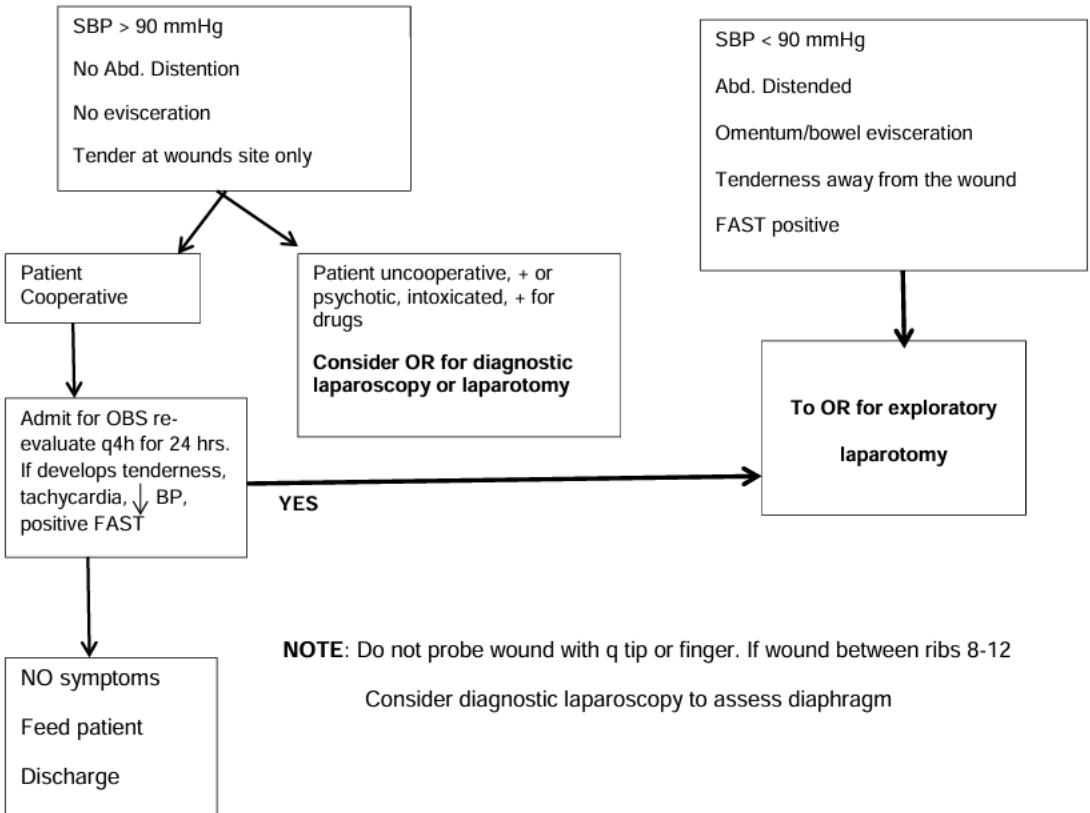
Penetrating Abdominal Wound – Stab Wound

**Location:**

8<sup>th</sup> intercostal (ICS) to Groin Crease

Posterior axillary line to posterior axillary line

**Clinical evaluation**



**NOTE:** Do not probe wound with q tip or finger. If wound between ribs 8-12  
Consider diagnostic laparoscopy to assess diaphragm