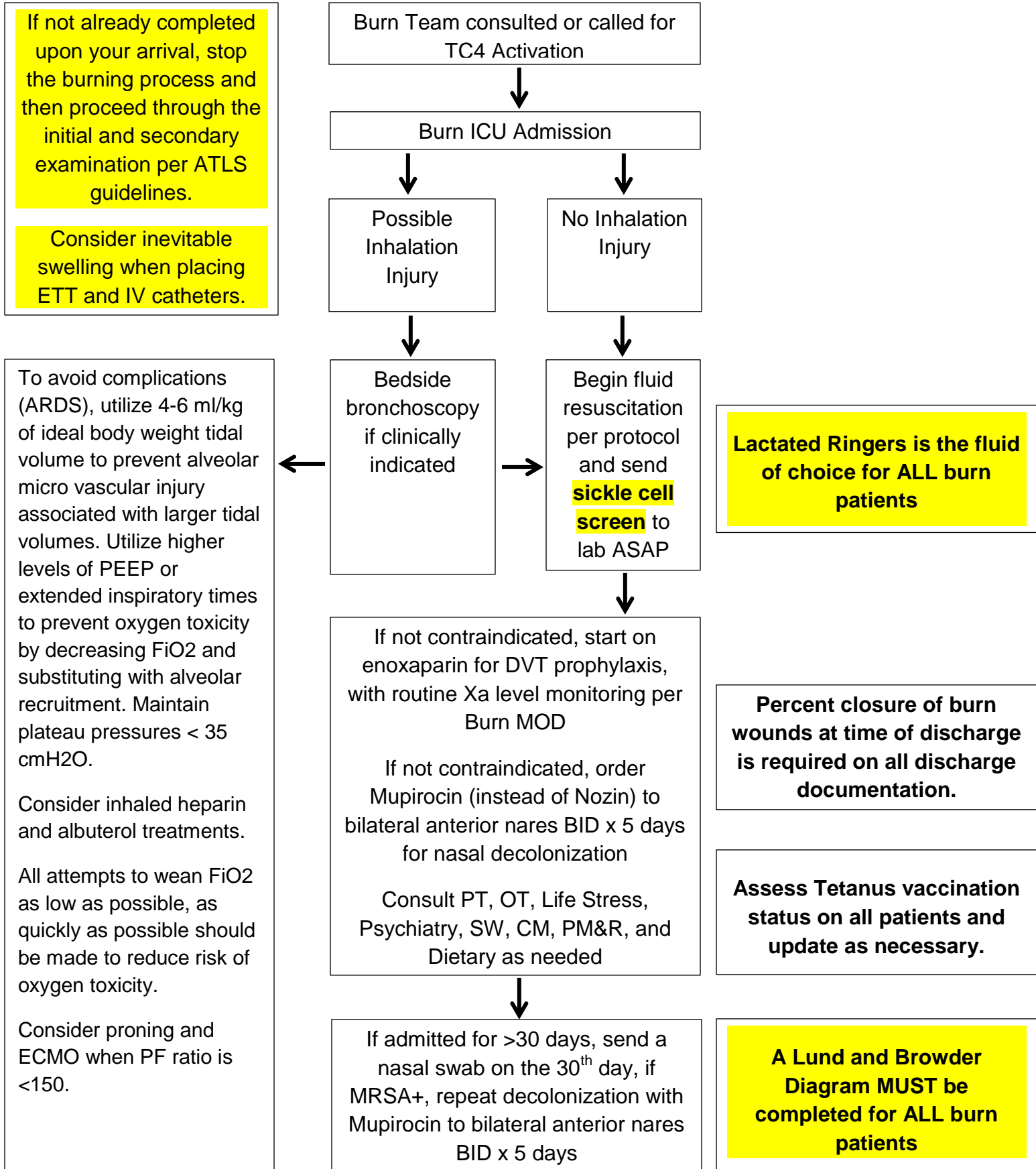


**Guidelines for Initial Evaluation of the Adult Burn Patient with >20% TBSA**



References:

1. Lin H, Faraklas I, Cochran A, Saffle J. Enoxaparin and antifactor XA levels in Acute Burn Patients. *J Burn Care Res*;2011;32:1-5.
2. Faucher L, Conlon K. Practice guidelines for deep venous thrombosis prophylaxis in burns. *J Burn Care Res* 2007; 28; 661-3,
3. Wibbenmeyer LA, Hoballa JJ, Amelon MJ, et al. The prevalence of venous thromboembolism of the lower extremity among thermally injured patient's determined by duplex sonography. *J Trauma* 2003; 55:1162-7.
4. Harrington DT, Mozingo DW, CanicioL etal. Thermally injured patients are at significant risk for thromboembolic complications. *J Trauma*. 2001;50:495-9.
5. Kim, J.J., Blevins, M.W., Brooks, D.J., et al. Successful control of methicillin-resistant Staphylococcus aureus outbreak in a burn intensive care unit by addition of universal decolonization with intranasal mupirocin to basic infection prevention measures. *American Journal of Infection Control* 2019; 47:661-665
6. Determann, R.M., Royackers, A., Wolthuis, E.K. et al. Ventilation with lower tidal volumes as compared with conventional tidal volumes for patients without acute lung injury: a preventive randomized controlled trial. *Crit Care* **14**, R1 (2010). <https://doi.org/10.1186/cc8230>
7. Fuller, B.M., Mohr, N.M., Drewry, A.M. et al. Lower tidal volume at initiation of mechanical ventilation may reduce progression to acute respiratory distress syndrome: a systematic review. *Crit Care* **17**, R11 (2013). <https://doi.org/10.1186/cc11936>
8. American Burn Association. (2018). Advanced burn life support.
9. American College of Surgeons. (2018). Advanced trauma life support 10<sup>th</sup> edition.