



Emergency Escharotomies

Escharotomies are the incising the burn eschar down to the fat done to relieve the pressure in the affected limb secondary to edema from the original injury and resuscitation.

The burn eschar unlike normal skin is no longer distensible and a circumferential full thickness burn does not stretch with the development of edema of the underlying tissues. This leads to elevation of pressure within the affected limb as edema develops that can compromise capillary blood flow to the tissues including muscle and nerves. The ischemic injury will begin well before loss of palpable pulses in the affected extremity.

Risk factors for escharotomies:

- Circumferential burns
- Burn size that requires resuscitation
- Delayed presentation
- Associated trauma
- Third degree burns
- Electrical burns associated with circumferential burn.

Patients at risk require hourly neurovascular checks.

Modalities that may be used to evaluate for elevated compartment pressures and need for escharotomies are listed below

1. Use of the Striker to measure compartment pressures: Positive results would be a compartment pressure of 30 mmHg
2. Use of pulse oximetry to look for decreased perfusion. Look for a drop below 95%, especially if compare pulse oximetry against normal extremity on contralateral side. If using pulse oximetry one must ensure drop in pulse oximetry is not to systemic response such as hypoxia or hypotension.

Majority of escharotomies are done within the first 24 to 48 hrs of burn injury.

Instruments required include:

- a scalpel and electrocautery for hemostasis.

Care of escharotomy wounds:

- Areas that are to undergo escharotomies should be prepped with betadine after debridement of the wounds have occurred. Incisions should follow lines on diagram and watch for injury to nerves listed.

How to perform escharotomy:

- The incisions made during the escharotomies should divide the eschar down thru to the fat.

- Once divided, the tension in the involved extremities should improve along with the vascular exam.
- If perfusion of the involved extremity does not improve after escharotomy, then the possible need for fasciotomy of the involved extremity should be considered.

Anesthesia/Sedation needed during escharotomy:

- If escharotomies are to be done in the burn ICU, Ketamine with versed is adequate anesthesia for an intubated patient.
- If patient is not intubated then will need general anesthesia in the OR.

Special considerations:

- For burns that require resuscitation and have associated circumferential burn injury(s), should consider doing escharotomies after wound debridement but before dressings applied.
- Circumferential truncal burns may contribute to development of abdominal compartment syndrome and restrict ventilation. This can present as elevated peak pressures and with decreased tidal volumes and elevated intrabdominal pressures. Doing escharotomies for the trunk may help with ventilation and decrease intra-abdominal pressures. After escharotomies are completed, the patient should show improvement in peak pressures and decreased in bladder pressure measurements.
- For patients with circumferential burns to trunk requiring resuscitation doing truncal escharotomies at the time right after debridement of the burns may be reasonable.

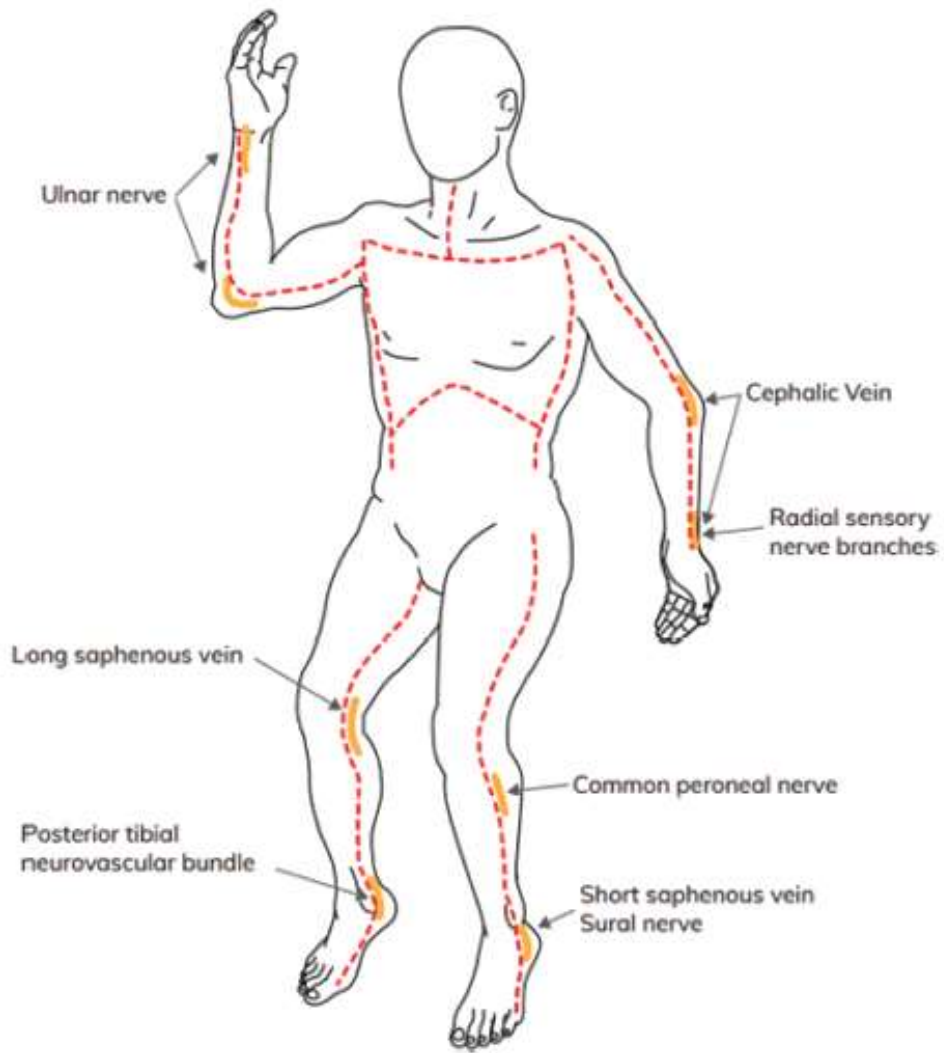
Care of burn wounds with escharotomies.

- For these burn wounds with escharotomy incisions we usually use Silvadene cream and wrapped with burn gauze and kerlix.
- Extremities are elevated to level of patient's heart and changed daily.
- No splints or ace wraps are used in the 48 hours following a burn injury to avoid negatively affecting the perfusion to the affected extremity during the edema formation phase of the acute burn injury.

Pitfalls in doing Escharotomies

1. Performing inadequate escharotomies that do not allow adequate separation of the incision edges.
2. Failing to reassess circulation of limbs treated with escharotomies
3. Not performing adequate hemostasis of escharotomies
4. Failures to detect a fascial compartment syndrome after escharotomies are done. This especially true for patients that have sustained high voltage electrical injuries (greater than 1000 volts) or burns associated with associated trauma such as crush injuries.

Truncal and Extremity Escharotomy Incision



Resources

1. Mario Eduardo Pereira Monteiro de Barros et al. Revisiting Escharotomy in Patients with Burns in Extremities. *J of Burn Care and Research*. July/August 2017, Vol. 38(4):pp e691-699
2. C. Caleb Butts et al. Surgical Escharotomy and Decompressive Therapies in Burns. *J of Burn Care and Research*. March/April 2020, Vol. 41(2): pp 263-269
3. Lesley Wong and Robert J Spence. *Hand Clinics*. May 2000, Vol. 16(2): pp 165-174