

DECEMBER 2023



2023 Annual WSSS Lectureship Dr. Scott Dulchavsky



Inside this issue:


2023 Annual WSSS Lectureship	1-4
Detroit Trauma Symposium	5-14
Dr. William Cox shares a memory of Dr. Arthur	15
ACS Clinical Congress	15
Surgical Grand Rounds	16-22
Erratum	22
Down Memory Lane	23-24
WSU Conferences	25
WSSS Dues	26
WSSS Members	27-28



2023 WSSS OFFICERS

- President:**
Larry Narkiewicz (WSU/GS 2004/09)
- Vice-President:**
Joseph Sfera (WSUGS 1991)
- Secretary-Treasurer:**
Bruce McIntosh (WSU/GS 1989/94)
- Members-at-Large:**
Jay Dujon (WSUGS 2011)
Anita Antoniolu (WSUGS 1998)
- Resident Member:**
Paige Aiello
Molly Belisle

The theme of this presentation had to do with surgical vulnerability. Following completion of his surgical residency, Dr. Scott Dulchavsky (WSU/GS 1983/88) spent some time at Stonybrook Hospital in the beautiful area of Long Island, New York where he worked with Dr. Evan Geller (WSUGS 1987) where they were actively involved in operative surgical care, teaching of students and residents, and clinical and basic research. While there, Dr. Dulchavsky had the opportunity to treat a 33-year-old man who had been involved in an MVC and shortly after arrival, had evidence of hypotension. Based upon the clinical findings and imaging studies, he was taken to the operating room where he had a splenectomy for a Type 4 splenic injury. Postoperatively, he had some hypotension, and Scott asked one of the senior surgeons there for an opinion. The senior surgeon indicated that he needed to take the patient back to the operating room for residual bleeding, and Scott asked for his assistance. They took the patient back to the operating room, controlled the bleeding, and the patient did quite well. Dr. Dulchavsky had the feeling that he was inadequate and that he should have achieved hemostasis during the first operation. He described this as his first “kick” in terms of threatening his confidence.



Dr. Scott Dulchavsky
2023 WSSS Lecturer

He then described a patient who came in after a small plane crash with multiple injuries, and the patient had a very severe liver injury for which he had to operate on several occasions. The patient was a big time drug dealer from Columbia, and the patient finally did okay, but he described the need to re-operate on his patient on different occasions as a “warning” about his inadequate surgical skills as he continued to punish himself for not being a perfect surgeon.

After a successful stint at Stonybrook, Dr. Dulchavsky returned to WSU and was actively involved in all of the central Detroit Medical Center hospitals. He described a “harder kick” which occurred when he operated upon a 23-year-old woman who had severe acute cholecystitis. The operation was begun as a laparoscopic cholecystectomy, and he watched a fifth year and a third year resident dissect the gallbladder down from the liver, and

Continue page 2

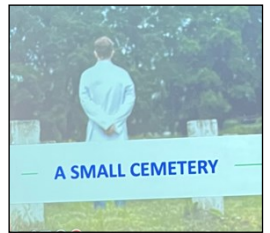


DECEMBER 2023

	<h2>2023 Annual WSSS Lectureship</h2> <h3>Dr. Scott Dulchavsky</h3>	
---	---	---

when the gallbladder was removed, they realized there was an injury to the common bile duct. He called for surgical assistance, and they reconstructed the common hepatic duct to a Roux-en-Y hepaticojejunostomy. He then had to re-live this case on a number of occasions when it was presented at the Morbidity and Mortality conference when he received extensive criticism and felt personally humiliated. The “final kick” occurred when there was an internal investigation of this case, and questions were raised about credentialing. He described how these problems sometimes end up in the courtroom where many different opinions are expressed and one is judged by a jury of “peers.” He also described some of the things that occur with so-called “expert witnesses” who will sometimes say anything in order to get a good payment.

Dr. Scott Dulchavsky discussed the problem of moral injury that occurs to the surgeon who has surgical complications in his presentation, “A Small Cemetery,” on 11/08/2023. He described that the self-recrimination is one of the contributors to surgical burnout. He admitted that he is not an expert on moral injury but emphasizes that this is something that has to be considered in the training of a surgical resident. One of his favorite books, “The Making of a Surgeon,” by Dr. William Nolen emphasizes the importance of mentoring. The traditional upbringing for the surgeon is that surgeons don’t cry over their mistakes; they just simply hold it in. Other aspects of surgical training are related to the statements, “If you are on call every other day, you are going to miss one half of the cases,” and surgeons are “invincible” and sometimes have poor empathy for the complications of others since surgeons cannot be “vulnerable.” The book by Brene Brown describes that all of us are vulnerable and presented a treatise on vulnerability. He quoted the work of Rene Leriche, the well known vascular surgeon, who talked about the complications that end up in the cemetery. Dr. Dulchavsky described his small cemetery where many of his complications have led to vulnerability and have been shuffled off to the past. He pointed out that there is a place for changes and that there has to be a code for dealing with failures.



He talked about the problem of death and dying in the operating room and how having serious complications is the type of “kick” which leads to failure and self-doubt and raises the question as to whether one is entitled to be a surgeon. The subsequent “fall” follows when things seem to spiral out of control with loss of sleep and severe depression. When this occurs on a long-term basis, one needs to call out to colleagues for help. The “guilty” surgeon becomes the victim who things about quitting. The “recovery” relates to the process of eventually getting over it and forgiving oneself, least the guilt complexes lead to early retirement or actually suicide.

Continue page 3




DECEMBER 2023



2023 Annual WSSS Lectureship Dr. Scott Dulchavsky



In February of 2009, Dr. Dulchavsky became involved with NASA and during this time made many contributions to the space program as it relates to interpreting ultrasound while in space. He described how failures within the space program could lead to “moral injury” and cause the leaders of the space endeavors great psychological distress. He even described the activities in the Trojan War as described in the Iliad and the problem of betrayal and distrust that was identified during this great struggle. Moral risk also extends to others who are vulnerable and unprepared emotionally to deal with complications and the importance of having social support in all of these complicated activities. These moral insults can occur because of sins of commission, sins of omission and, worst of all, betrayal.



Dr. Larry Narkiewicz, President of the WSSS, introduces Dr. Dulchavsky

Dr. Dulchavsky discussed the importance of considering these factors when running a Department of Surgery. The junior faculty are potentially more vulnerable as he recalls the procedure where he divided the common bile duct.


Dr. Dulchavsky discussed some of the approaches that the military (U.S. Marine Corps) has taken for different levels of officers in order to deal with complications up front so that they don't become destructive to the individual officer. The same is true for the surgical residents, and there has to be a communication system, whereby the residents can communicate with their faculty and work together to deal with these complications without having self-destructive ideology. The scars of these complications will hopefully allow the young surgeons to become stronger, rather than crushing the young surgeon because of inadequate support in this vulnerable situation. Preventive measures have to be identified, and complications have to be dealt with promptly in order to prevent early burnout.

For the military system, he described the “yellow” sign, which is a warning and is associated with fearfulness, depression, anger, and illogical statements associated with loss of confidence, which may even lead to suicidal or homicidal thinking. The 2020 Clinical Congress of the American College of Surgeons dealt with these mental challenges and the importance of peer support in a timely manner so that such intervention protects the training program and protects all of the surgical residents. It is important to be open about “vulnerability.” He also emphasized that all surgeons have complications, some of which are preventable, and that support systems must be in place in order to prevent excessive stress and guilt. He advocated the development of a “Wellness Task Force” which should be built into each Department of Surgery in order to help deal with these issues.

Following his excellent presentation, there was an active question-and-answer session.

DECEMBER 2023

2023 Annual WSSS
 Lectureship Dinner



Dr. Scott Dulchavsky receiving the WSSS Icon Award from Dr. Lawrence Narkiewicz and Dr. Lawrence Diebel



(Front left to right) Drs. Solhee Lee (WSUGS), David Edelman (WSU/GS 2002/09), Heather Dolman (WSU/GS 2000/06), Erin Field (WSUGS), Alfred Baylor (WSUGS 2005), Anna Ledgerwood (WSUGS 1972), Randy Smith (WSU/GS 1981/86), Arthur Carlin (WSU/GS 1991/98), Kellie McFarlin (WSU/GS 2003/08), and Mark Herman (WSU/GS 1994/2001)



(Left to right) Dr. Lawrence Narkiewicz (WSU/GS 2004/09), Dr. Ryan Rosen (WSUGS 2025), and Dr. Joseph Sferra (WSUGS 1991)



(Left) Dr. Keith Hinshaw (WSU/GS 1982/87) and Dr. Paul Corcoran (WSUGS 2004)



DECEMBER 2023



The 71st Annual Detroit Trauma Symposium (DTS) occurred on November 9-10, 2023 at the MGM Grand Casino and Hotel in Detroit. As usual, Dr. Diebel was the organizer of the DTS and had a very successful program with a large number of attendees, both in person and online. The initial program began with the “Sunrise Sessions” where the participants had the opportunity to enjoy breakfast while listening to short presentations by the visiting experts.

The main Thursday morning session began with a lecture by Dr. Paula Ferrada from the Inova Center in Falls Church, Virginia who discussed “Resuscitation 2023: Circulation First.” Dr. Ferrada challenged the classic ATLS guidelines regarding Airway, Bleeding, and Circulation (ABC’s). She described how the severely injured patient is often “gasping” for breath, and this represents decreased circulation to the brain with vasoconstriction, including the cerebral vessels. When the patient is immediately intubated, medications are usually given, and these medications interfere with the protective “gasping” response, leading to rapid death. She described how the “Golden Hour” should be re-defined as the “Critical Ten Minutes.” Besides placing pressure over the injury sites to prevent overt bleeding or to place a proximal tourniquet as part of the “Stop The Bleed” takes priority since an Emergency Department thoracotomy will not be successful if the patient is still bleeding. She described some patient examples. The first was a patient who was hypotensive and gasping for breath in whom circulation must be actively restored as part of an E.D. thoracotomy with clamping of the thoracic aorta performed because of severe acidosis and impending death. She described how this provided restoration of cardiac and cerebral flow in order that laparotomy could be performed for control of a badly injured liver. She also described a patient who had an injury to the right upper quadrant and was hypotensive in whom the placement of a REBOA in zone 1 followed by intubation in the operating room allowed for a right chest incision to be made and a severe lung injury to be repaired. Lastly, she described a patient who had a gunshot wound to the left supraclavicular area, leading to severe hypotension requiring initiation of the Massive Transfusion protocol on the way to the operating room. Intubation was performed following the emergency E.D. thoracotomy with aortic clamping which preserved flow to the brain and heart while the subclavian artery was repaired. The patient developed acute kidney injury (AKI) from which he survived by appropriate renal support. She finished by emphasizing that patients who are given medicines to provide for intubation prior to having vascular restoration are probably going to die.



Dr. Paula Ferrada

The next presentation at 9 a.m. was provided by Dr. Marc de Moya, the Trauma Director from the Medical College of Wisconsin in Milwaukee. He presented on the “Role and Results for Surgery in Patients with Rib Fractures.” He began by presenting a patient who had a fall from a height and presented to the Emergency Department with stable vital signs but severe chest pain due to multiple bilateral rib fractures. The imaging studies identified that there were over 14 rib fractures. He showed a second patient who had gotten hit by a car while riding a bike, and this patient presented with a crushed chest on the left side with rib fractures in the left

Continue page 6

DECEMBER 2023



chest cavity and diffuse subcutaneous air. The left chest was compressed by about 20%. This patient had a flail chest, and he pointed out that clinically obvious flail chests are associated with about a 5% mortality rate. He went through some of the early history of multiple rib fractures and flail chest when external fixators were placed around the ribs and attached to weights as a crude form of traction. This technique for therapy became less popular when positive pressure ventilation became available and allowed for “internal” fixation. He quoted Papyrus papers from 1600 B.C. which described the treatment of rib fractures. The new treatment is the internal fixation, and he reported on one of the early randomized controlled trials out of Japan done in 1990 which demonstrated that patients having fixation do better than patients treated with positive pressure ventilation. He also described a number of other prospective randomized trials which tend to show that patients with bad injuries do better with internal fixation. He finished his presentation by describing how the surgical approach now uses smaller incisions and involves more muscle sparing which contributes to better results. He also showed the different types of metallic plates which have become popular and have facilitated operative repair. Some potential indications would be in patients with five rib fractures and obvious flailing, patients with 3-5 rib fractures with severe discomfort, patients with symptoms due to long-term non-union, patients with severe deformity compromising vital capacity to less than 30% of normal, and patients with incentive spirometry values of less than 500 mL.



Dr. Marc de Moya

Dr. Larry Diebel (WSU/GS 1980/86) then moderated a panel discussion including Dr. Ferrada; Dr. Raul Coimbra, Director at Riverside University Health System in Moreno Valley, California; Dr. Edward Harvey, Director at McGill University in Montreal, Quebec; and Dr. Marc de Moya. The different topics that were discussed in depth were the identification and treatment of an extremity compartment syndrome. It was emphasized that when the superficial posterior compartment, the medial compartment, and the lateral compartment are decompressed, there is often a significant lowering of pressure in the deep posterior compartment, negating the need for deep posterior compartment fasciotomy. They discussed the role of intubation in patients with traumatic brain injury and pointed out that decision making has to be based upon the pulmonary findings. Dr. Ferrada emphasized that the use of REBOA for patients with bleeding from chest trauma is rarely needed except as a means of restoring circulation to the brain and heart. They also discussed the approach to the subclavian artery and how to get control above and below the clavicle. They discussed the value of using the aortic compressor in getting control of the aorta above the celiac artery rather than doing a complete mobilization of the left sided intraabdominal organs.

Dr. Raul Coimbra from the Riverside University Health System made the next presentation, “Trauma Publications That Changed Clinical Care in the Last Two Decades.” Dr. Coimbra is the current chief editor of the Journal of Trauma and, therefore, is exposed to hundreds of publications each year. He described how damage control resuscitation initially proposed by Dr. Rotundo in 1993 in patients with hypotension, hypothermia, and

Continue page 7

DECEMBER 2023



coagulopathy has produced tremendous improvement in the long-term survival. He identified the damage control resuscitation first described by Dr. Holcom beginning in the pre-hospital setting as also augmenting long-term survival. He also emphasized the importance of calcium supplementation as an aid to the damage control resuscitation. REBOA began in 2010 and has allowed for patients with intraabdominal and pelvic injuries to be successfully resuscitated without the need for an Emergency Department thoracotomy. He also identified the TEG technique for monitoring the status of coagulation as being an important part of successful resuscitation and emphasized the value of plasma, platelets, fibrinogen, prothrombin concentrate, and TXA when certain conditions are identified on the TEG. The use of splenic embolization has been a great advance but should be used only when patients have symptomatic bleeding since prophylactic splenic embolization for splenic rupture may lead to splenic necrosis necessitating splenectomy. He also emphasized the importance of pelvic packing which has allowed for many patients to have hemostasis without the use of embolization although the two procedures may be synergistic. Finally, he emphasized the value of cerebrovascular angiography by computed tomography in screening for cerebrovascular injuries in patients with injuries of the neck and upper thorax.



Dr. Raul Coimbra

The next presentation by Dr. Ferrada was entitled, “Cardiac Injuries: Tips and Tricks in Management.” Dr. Ferrada described the findings in patients with penetrating cardiac wounds which include the Beck’s triad of hypotension, distant heart tones, and paradoxical hypotension. Ultrasonography has provided a tremendous advantage in making the diagnosis which used to be made by clinical examination. Once the diagnosis is made, pericardiocentesis may improve circulation by increasing the volume of left ventricular contraction while the patient is taken to the operating room for a left anterior thoracotomy. Occasionally the bleeding is located more on the right side so that the left anterior thoracotomy has to be extended over into the right chest as a “clam shell” incision. Many people prefer to do the repair with the use of pledgets to prevent underlying injury to the cardiac muscle when it is sewn (the editor prefers to avoid pledgets and that the person tying the knots has the assistant surgeon holding another suture at the perfect position point while the knot is secured; this avoids some of the postoperative pericarditis seen with pledgets). She also emphasized the approach to blunt cardiac injury which is identified by the combination of an altered electrocardiogram and increase in troponins. Whenever a patient has this combination, they should be admitted to a monitored unit if they do not need to go immediately to the operating room. When ultrasound demonstrates pericardial fluid, a pericardiocentesis may be performed on the way to the operating room if the patient is hypotensive; alternatively, the patient is taken directly to the operating room for operative intervention.

Dr. Marc de Moya made the next presentation entitled, “Management of Traumatic Hemo/Pneumothorax.” Dr. de Moya presented a scoring system as identified by computed tomography for chest injury ranging from isolated rib fracture to multiple fractures with or without flail chest. He emphasized that the treatment of a


Continue page 8

DECEMBER 2023



pneumothorax depends upon the size and that patients with pneumothorax and lung collapse of less than 3.5 mm do not need any type of chest decompression initially. He showed how 93% of these patients would do well without any invasive treatment and that the remaining can have a delayed insertion of a pigtail catheter if the pneumothorax worsens. He also disagreed with the classic opinion that has been expressed over the years that patients who are to be intubated and put on positive pressure ventilation should have a prophylactic thoracic decompression. He indicated that 96% of these patients never need any type of decompression even though they are receiving positive pressure ventilation but he is not sure whether this applies to people who are receiving PEEP. Likewise, increasing the mean airway pressure does not appear to have an effect on the small pneumothorax. He also emphasized that the pigtail catheter typically provides good decompression of air and sometimes blood with controlled studies showing that the results are comparable when comparing the pigtail catheter and a chest tube. The same principle applies when patients have a hemothorax in that pigtail catheter provides excellent egress of blood, which in the past has typically been treated with a chest tube of at least a 26 or 28 gauge. He finished by discussing contained hemothorax and how this can be reduced and how the incidence of this can be reduced through the chest tube or pigtail catheter, thus decreasing the need for subsequent intervention with a second chest tube or endoscopic thoracoscopy.

The next section was the question-and-answer panel moderated by Dr. Diebel. The panel members emphasized that cryoprecipitate may be a good additive in patients who have evidence of coagulopathy on the TEG, which is performed at the bedside. They recommended that TXA is beneficial if given within the first three hours after severe bleeding. They re-emphasized the potential for splenic embolization causing infarct or being associated with re-bleeding in at least 25% of patients. This goes counter to some of the prior recommendations that embolization of solid organs be done for patients who have a blush but are clinically stable. They also discussed the role of intervention for retained hemothorax, emphasizing that when the volume is 500 mL, intervention is needed within the first 48 hours. The role of pelvic packing is beneficial for some pelvic fractures and may be a bridge to angiography and embolization of pelvic bleeding. They also discussed the use of embolizing gel foam while in the operating room in a patient who is undergoing pelvic packing. All of the panelists were in agreement regarding the use of calcium supplementation for every six units of RBC transfusion (the editor recommends one unit per every five transfusions).



Dr. Larry Diebel

The session provided during the lunch hour was delivered by Dr. Scott Dulchavsky (WSU/GS 1983/88) from the Henry Ford Health System. Dr. Dulchavsky, the former Chief of Surgery at Detroit Receiving Hospital prior to becoming the Chairperson at Henry Ford Hospital, is a member of the NASA space program and is actively involved in many things related to Lunar Earth Orbit (LEO). He talked about how directing surgical procedures on Mars from Earth is very difficult because there is an 18-minute delay from the time the words leave Earth and reach Mars and vice versa. Therefore, the astronauts have to be quite experienced with

Continue page 9



DECEMBER 2023



simple trauma care. The gravity of space is decreased and consequently, the astronauts have a loss of one mass which can be painful because the vertebral column lengthens by 2 to 3 inches. The zero gravity affects the muscles, the eyes, and the immune system. Future vehicles will be coming down directly on Earth, and there is fear as to what the impact might do to the weakened vertebral column. He described the different aspects of the space capsule and how this makes movement quite difficult. There is “dust” on other planets, and the effect of this on the lungs is not known. They do know that there are immunologic malignancies that develop in astronauts for reasons that are unknown. The Artemis Mars program will be a step further in the space program and is planned to be instituted within the next two years. Medicine from Earth has to be directed by telemedicine, and there has to be a support system in place. One of the big concerns about astronauts is functioning of the toilet. Once the astronauts have returned to Earth, there may be problems with pain as the body becomes readjusted to Earth’s gravity. The zero gravity conditions require careful utilization of the ultrasound machine and instruments; astronauts do not like to see a scalpel floating by them. The astronauts are exposed to “mimic” operations and could probably do an appendectomy. They are all familiar with ultrasound and are able to perform a percutaneous cholecystostomy. The ultrasound allows for identification of pneumothorax, long bone fractures, and muscle injuries. Dr. Dulchavsky was very active in teaching members of the space program about these techniques. Ultrasound of the eye can be used to identify intracerebral pressures. He pointed out that guiding an appendectomy from Earth is difficult because of the 1-minute time delay in voice transfer from Earth to Mars. The astronauts are quite familiar with the FAST technique for identifying abdominal injury and learned how high frequency ultrasound can be used for coagulation. In great distress, the astronaut can be returned to Earth for definitive therapy on Earth.

Following the luncheon lecture, the Afternoon session was begun by Dr. Samuel Mandell, the Trauma Director at the university of Texas Southwestern/Parkland Health in Dallas, Texas. His lecture was entitled, “Burn Resuscitation: Parkland Formula 2023.” Dr. Mandell talked about the resuscitation for severe burns and highlighted the classic Parkland formula. He emphasized that crystalloids alone aren’t used because of the concern for “leaky” capillaries and that colloid of either albumin or plasma would be given after the capillaries have become less permeable. He talked about the correlation between the percent of burn and mortality percent and emphasized the old dictum that the mortality would be close to the addition of the percent of total body surface area burn and the patient’s age. He presented many examples of burn care. There are a number of burn dressings which can be used in certain circumstances. Some of these dressings seem to work, but there are no prospective randomized trials, and the cost of these dressings sometimes runs into the many thousands of dollars for a large burn. There are artificial dressings for superficial burns and burns that go deep beyond the dermis. The use of the many artificial dressings needs to be studied more in order to determine if they are more effective than the less expensive dressings. He finally discussed the different aspects of reconstruction in patients with severe burns, including not only skin coverage but flap formation.


Continue page 10

DECEMBER 2023




The next presentation was made by Dr. Rochelle Dicker, the Trauma Director from the University of California in San Francisco. Her presentation was entitled, “Trauma informed Care: It’s Not Just Being a Good Health Care Worker.” Dr. Dicker emphasized the importance of team work and how communications are an important part of providing good care for injured patients. The teamwork begins in the pre-hospital setting, and there has to be accurate and timely information about patients who are being brought into the trauma center. Once the patient arrives, there are many individuals with assigned tasks, and it is important to keep priorities in proper order as each individual knows his or her assignment in the early resuscitation and evaluation of the injured patient. Communications with those providing imaging studies, those providing blood and blood products from the laboratory, and the operating room for patients who are going promptly for operative intervention are critical to a successful outcome. Each person may be doing their own assigned job well, but unless there are excellent communications between all members of the treating team, the outcome may not be optimal. Also included in these communications are the police authorities who have their own objectives and family members who are concerned for the welfare of their loved ones. She gave several examples where communications may be improved.

The next presentation was made by Dr. Raul Coimbra and was entitled, “The ACS, AAST, EGS Verification Program.” Dr. Coimbra went into detail about the origin of the American College of Surgeons verification program and how this program has markedly improved the level of care by providing guidelines for both large and small trauma centers to facilitate a good outcome in injured patients. This verification program expanded rapidly and provided excellent improvement in patient care. The verification program identified the institutional criteria, the physician criteria, and the administrative criteria needed for a good outcome. This process has been extended to Emergency General Surgery (EGS) and will likely be combined as one ACS Trauma Verification/Emergency General Surgery verification since so many of the activities are similar. The evolution of this combined program continues to evolve rapidly and be responsive to timely intervention with guidelines showing what needs to be done in the Emergency Department, the operating room, and the intensive care unit



Dr. Raul Coimbra

Dr. Samuel Mandell provided the next presentation entitled, “Cover Me: Update on Skin Substitutions for Trauma and Burns.” This presentation discussed different types of dressings and tried to identify the ideal dressing for different wounds. This involves the combination of the correct moisture, ability to oxygenate the underlying tissues, and removability when the time for the dressing has reached its end point. There are many different classes of wound dressings which are designed to deal with cells, different layers of thickness, and ease with dressing changes. The materials that are applied may be temporary or permanent, and they may be either partial-thickness or full-thickness dressings depending on the depth of the wound. Once the wound has recovered to the point where there is minimal dermis, a split-thickness skin graft can be applied



Dr. Samuel Mandell

Continue page 11



DECEMBER 2023



with the expectation that there will be a good long-term result. For deeper wounds, the use of the VAC may be a proper stepping stone prior to the autologous skin graft. Acellular grafts have been developed from different fish as a replacement for the previously used porcine grafts. These xenografts provide a dressing, and there have been excellent results with burns but not so much with trauma. Allografts such as cadaver grafts also can be developed in a cellular and acellular format in the form of Alloderm. The guideline or objective is to have a live dermis upon which a split-thickness skin graft is likely to take. Some of the cellular grafts contain keratinocytes which is good for deep wounds and may facilitate healing by increasing epithelial growth factors.

Dr. Rochelle Dicker provided the next talk which was entitled, "Violence Intervention: What Can We Do in Healthcare?" She emphasized the so-called "risk" of patterns which establish a greater likelihood for injury. There are many unmet societal needs which created an environment for violence, and these needs have to be addressed. Many younger patients are angry with their environment, resulting in severe injury, and one needs to branch out and prevent this anger from getting out of hand. She talked about the toxic stresses which include poor education, physical debilitation, mental deficiencies, and others which lead to violence, homicide, and suicide. Many of these social needs are not being covered. She emphasized the importance of the American College of Surgeons trauma program to emphasize evaluation and support for these social concerns that deal with violence. She pointed out that there have been some advances in these activities during the Obama era, and one needs to determine whether these changes are improving outcome as it relates to violence.



Dr. Rochelle Dicker

The next session was a question and answer session of the above presenters, and this was moderated by Dr. Michael White (WSU/GS 1990/97). There was an active discussion regarding all of these issues and included many questions that came from the audience.

Following the question-and-answer session, Dr. Anna Ledgerwood (WSUGS 1972) presented the panel of experts with many cases identifying patients who were treated over the past period of time at the Detroit Receiving Hospital. The cases were quite complicated and often associated with complications in order to see how the panel of experts would possibly have handled the injuries differently. As usual, this was a very complex and well appreciated session, and the experts were truly excellent in their decision making in the sequential care of these patients.

Dr. Chad Bell, the Trauma Director at the University of Calgary in Alberta, made the next presentation entitled, "Utilization of Hybrid O.R. for Trauma." Dr. Ball went through the very complicated history that led to the development of the hybrid O.R. The concept began in Scotland over 20 years ago, and Calgary became the second place to establish this entity. Organizing the hybrid O.R. requires participation from all members who are involved in the care of the severely injured patient, including administration, emergency department,

Continue page 12

DECEMBER 2023



imaging services, laboratory services, and the operating room. Things that might be performed in three or four different places are now performed in one confined unit so that everybody has to know their specific assignment and not compromise their colleague who has a different assignment. There are many advantages to the hybrid O.R. in that it allows for a patient with multiple injuries to simultaneously have placement of a chest tube, starting of fluid and blood, and inserting a groin catheter in order to subsequently embolize a pelvic bleeder. The patient can also undergo operation without being moved to the large operating suite. The cost of a hybrid O.R. is quite expensive and, as Dr. Ball pointed out, costs more than \$6,000,000 Canadian dollars. They have a strong support service in their community so they were able to put on fundraisers in order to facilitate the establishment of this unit. During the design process, they had to determine how all of the appropriate equipment that might be used by different services has to be immediately available within a confined area. The cost of this project can only be put into perspective when one looks at the cost/life saved ratio. Their quality analysis showed that certain patients with bad injuries cannot be saved, whereas others have potentially treatable injuries. They have demonstrated that those with treatable injuries have had a 16% reduction in mortality due to the efficiency brought about by the hybrid O.R. One can then calculate on the basis of the cost/lives saved ratio how much a human life is worth. It was a very interesting and philosophical presentation.



Dr. Chad Bell

The next presentation was made by Dr. Todd Rasmussen and was entitled, “REBOA: When, Where, Who?” Dr. Rasmussen went into some of the history regarding the obtainment of proximal control of a bleeding vessel, particularly when that vessel is within the abdomen where one cannot get application of a tourniquet for compression. The concept evolved from the analysis of over 5,000 autopsies of those who were killed in action during military conflict. They determined that 75% of these injuries were non-survivable, whereas 24% had hemorrhage with a non-compressible location, such as the abdomen or sometimes in the upper extremity at the axilla. He also emphasized that the importance of developing control in an area of non-compressible hemorrhage could also apply to civilian usage. The history of proximal aortic control goes back at least half a century, and Dr. Ledgerwood’s paper about doing a left anterior thoracotomy and obtaining aortic control prior to entering the abdomen was discussed in detail. This paper emphasized that when you have a patient with a distended abdomen and hypotension, laparotomy will shortly lead to cardiac arrest and death. The question then arises as to what patients are best for REBOA, and it appears that patients who have non-compressible injuries in zone 2 of the abdomen or in zone 3 of the pelvis can be stabilized by rapid placement of REBOA and that the balloon can be inflated to the appropriate level to restore vital signs as plans are made for definitive control of the bleeding. This may be achieved by laparotomy and a direct approach to the bleeding or can also be achieved by embolization of the pelvic vessels which have been partially controlled by REBOA.



Dr. Todd Rasmussen

Continue page 13

DECEMBER 2023




The next paper on program was presented by nurse Ashley Liebig and was entitled, “Development of New Staff and/or E.D. Trauma: Teaching Training, and learning in Stressful Environment.” Ms. Liebig emphasized the many challenges that are faced when new staff persons or emergency department nurses become involved in the injured patient and all of the teaching, training, and learning that must be provided in order to reduce the stress of resuscitating severely injured patients. She talked about the physical needs of being healthy and fresh when coming to work and the importance of safety as it relates to having a secure position. Any worker who is under threat of being fired is no longer going to be able to function in a stressful environment where the combination of love, self-esteem, and appropriate interrelationship with others is needed. Nurse Liebig talked about the importance of avoiding altercations, including the good things about work and having a pleasant working capacity in order to enhance the care of injured patients and maintain a long relationship with the trauma center.



Ms. Ashley Liebig

The next session was the question-and-answer panel of the above presenters, and this was moderated by Dr. James Tyburski (WSUGS 1992). Many interesting questions were provided from the audience which allowed for an expansion of their presentations.



(Left to right) Dr. Todd Rasmussen, Ms. Ashley Liebig, Dr. Chad Ball, and moderator, Dr. James Tyburski

The next presentation was provided by Dr. Rasmussen and was entitled, “Endovascular vs. Open Approach for Vascular Trauma.” Dr. Rasmussen highlighted the important changing technology which has evolved over the past generation so that endovascular surgery is becoming easier and more effective and, therefore, more popular. He emphasized that the military does not have many vascular surgeons so that the general surgeons have to become involved and develop all of the techniques needed to provide endovascular surgery for our injured soldiers. Industry is rapidly developing new stents, plugs, and coils in order to more successfully carry out the successful repair of vascular injuries without having to do an open operation. He also described how the new endovascular techniques can allow for repair of a pseudoaneurysm by stenting or even repairing an arteriovenous fistula. The use of endovascular surgery for rupture of the thoracic aorta has revolutionized this procedure so that now open repairs for a blunt thoracic aortic rupture have become a small minority. Endovascular procedures can also be used for the combination of repairing a vascular injury, followed by open repair and internal medullary fixation of a long bone fracture. The use of stents has an important place. Whenever a patient with a major vascular injury is treated at a place without facilities for doing open repair, he described different types of stents and how they can be placed and suggested that the patient has stent placement within four hours in order to optimize a good result.

The next presentation was made by Dr. Ball and was entitled, “Management of Major Hepatic Trauma.” Dr. Ball described the overall approach to patients with both blunt and penetrating liver injuries. The resuscitation

Continue page 14



DECEMBER 2023



is the same as has been described by many other papers in this symposium so that the focus has to be on the anatomy of the liver. All surgeons involved with the treatment of liver injuries must be familiar with the segments of the liver and the arterial and venous blood supply in order to facilitate successful treatment and to avoid injuries to critical vessels. The Pringle maneuver is an important adjunct in temporarily controlling bleeding which is coming from the hepatic artery or the portal vein but will not control bleeding which is arising from one of the hepatic veins. He emphasized that when one has back bleeding from one of the hepatic veins, one is likely going to have to enter the liver in order to get access and control. Mobilization of the liver, particularly the right lobe, is critical as is having the ability to utilize hand compression of the liver while dissection is carried down to areas of continued bleeding. He emphasized how electrocoagulation is an important aspect of the oozing that occurs from the injured soft tissue, whereas direct clamping, division, and ligating is required for medium-sized vessels that are crossing the liver and actively bleeding. The use of the inferior vena cava shunt was discussed and Dr. Ball pointed out that there are probably more papers describing the procedure than there are survivors. Packing is an important part of liver injury with some of the packs being removed 15 minutes after application after which no further bleeding is identified. When pack removal temporarily controls bleeding but bleeding recurs again upon pack removal, the pack needs to be left in place and the patient fully resuscitated with plans for re-operation and removal of the pack when the patient is stable and coagulation studies are normal.



Dr. Lawrence Diebel, Dr. Chad Ball, Dr. Todd Rasumussen, and Dr. James Tyburski

The next presentation was made by Dr. Larry Diebel and was entitled, “The Endothelial Glycocalyx in Trauma: Rewriting the Starling Equation.” The endothelial glycocalyx is a portion of the extracellular matrix and is made up of many different substances, including collagen. The extracellular matrix extends from the capillary wall to the cell, and the capillary, matrix, and cell work in a synergistic manner to allow the patient to survive. Dr. Diebel described many substances that affect the glycocalyx and the capillary wall which are associated with changes that result in increased movement of fluid and protein out of the capillary into the interstitial space. He emphasized how this is a very important part of the body’s response to hemorrhagic shock and that many more studies need to be performed so that the physician better understands how to adjust to these changes for the benefit of the patient.

Dr. Diebel then thanked everyone for their attendance and had drawing of raffles based upon the attendee’s visitation with the exhibitors. Prizes were provided for those who had their raffle ticket taken from the hat. He then announced the plans for the 2024 Detroit Trauma Symposium and adjourned the meeting.





DECEMBER 2023

Dr. William Cox Shares a Memory of Dr. Arthur Weaver

The story about head-and-neck surgeon, Dr. Arthur Weaver brought back a memory. He was having a quick lunch (yogurt in a plastic cup) in his office between classes. And in between spoonfuls of yogurt, he was teaching medical students. I was one of the medical students. He was telling us of the many hairdressers/beauticians he's operated on for oral cancer and why it was probably so prevalent among them. Seems they all would swish an alcohol-based mouthwash in the mouths between clients so as not to risk bad breath, and eventually developed mouth cancer when they got older. Needless to say, I took this lesson to heart and have avoided alcohol-based mouthwashes. Dr. Weaver was a teaching surgeon who contributed so much and I am sure he will be missed.

William M. Cox, M.D.

WSU Medical School Class of 1979




CLINICAL CONGRESS 2023

OCTOBER 22-25 / BOSTON, MA

Dr. Christopher Dente (WSUGS 2002) and Dr. Heather Dolman (WSU/GS 2000/06) have been on a recurring panel for the American College of Surgeons as moderators. On this panel they review trauma videos that participants have sent in to educate the audience on trauma care.

This year it was "Video Based Education VE-309" for the Trauma/Critical Care rack on Wednesday, October 25th, 2023 from 2:30-4:00 p.m. Below is a photo of them reviewing a trauma case.



Dr. Christopher Dente and Dr. Heather Dolman (seated) reviewing the video

DECEMBER 2023

SURGICAL GRAND ROUNDS

Liver Transplants: A Primer for the General Surgeon

The Surgical Grand Rounds on November 1, 2023, presented by Dr. Miguel Tobon (WSUGS 2020), was entitled “Liver Transplantation: A Primer for the General Surgeon.” Dr. Tobon emphasized that liver transplantation is relatively new and has been performed frequently for only the past approximately 50 years. He outlined the importance of liver anatomy, technical skills, indications, and comprehensive postoperative therapy including immunosuppression. He emphasized that there are many variations in liver anatomy so that careful review of all imaging studies is necessary in order to identify which variations might be present in any patient. A safe approach to the liver includes taking down the falciform ligament and mobilizing all of the multiple ligaments which extend throughout the surface of the diaphragm, including the bare area of the liver where there is potential for making a hole in the diaphragm; this can be easily repaired primarily. He spent some time describing the eight segments of the liver and the various segmental divisions for both the right lobe and the left lobe. One of the potential dangerous areas is the freeing up of the left hepatic vein which is formed by the merging of the venous drainage from the left lobe and the caudate lobe just anterior to the inferior vena cava. He described how mobilization of the right lobe of the liver is tedious, and when the right lobe has been mobilized anteriorly and to the left, one can identify the short hepatic veins which run directly to the inferior vena cava and have to be individually tied and divided if the right lobe is to be removed or if there is a total hepatectomy with transplantation. He described the Couinaud classification which defines segments 2 and 3 as making up the left lateral segment and segments 5 thru 8 making up the right lobe of the liver, with segment 1 being the caudate lobe just anterior to the cava. The hepatic artery provides about 20-25% of the blood flow to the liver and about 40% of the hepatic oxygenation, with the portal vein making up the remainder.



Dr. Miguel Tobon

The results of liver transplantation have improved markedly over the past 50 years. When this procedure was first started, there was a close to 50% mortality rate, whereas now the mortality rate is less than 10%. This is the result of better selection, which is augmented by the MELD (Model for End-Stage Liver Disease) score, which is routinely used in determining when patients are candidates for liver transplantation. The donors for liver transplantation come from both donation after circulatory death (DCD) and donation after brain death (DBD). The DBD donors are typically patients who have brain death but continue to have cardiovascular function. These donors are much more likely to have an excellent result since the liver has not gone through a period of ischemia compared to

Continue page 17



DECEMBER 2023

SURGICAL GRAND ROUNDS, cont.

Liver Transplants: A Primer for the General Surgeon, cont.

those patients who have donation after circulatory arrest. When the donor patient has hepatitis C, treatment of the recipient for six months leads to a 95% cure rate and thus salvage of liver function in the recipient. The 21st century has seen tremendous advances in techniques which incorporate minimally invasive procedures, including robotic techniques. During operation, extensive mobilization of the colon and right sided abdominal organs gives the surgeon much better exposure. Once full mobilization has taken place, the last part of the procedure is to divide the inferior vena cava just inferior to the atrium and the subhepatic site at the appropriate length to be placed into the recipient. Using this technique for arterial mobilization, the blood supply to the bile duct is preserved so that an end-to-end ductal anastomosis is usually successful. The most common reasons for receiving a liver transplantation include malignancies, hepatitis, and primary biliary cholangitis. Cholangiocarcinoma has traditionally been a partial contraindication to transplantation but is now being successfully treated with transplantation at the Mayo Clinic.

Dr. Tobon described some of the technical aspects of liver transplantation, including the right upper quadrant incision approach to all of the right sided organs and the careful dissection to the hilar area in order to minimize any small injuries to the hilar vascular structures. He described how all of this mobilization can be done with only partial occlusion of the main vessels so that hemodynamics are preserved during the procedure.

Early lack of hepatic function occurs in about 5% of patients. This occurs acutely and usually requires re-transplantation. Acute portal venous thrombosis requires an immediate reoperation for thrombectomy, whereas biliary complications and infectious complications are more frequent but can usually be managed non-operatively. He reported that liver transplantations do not require induction therapy and pointed out that the liver is more tolerant of rejection compared to the kidneys. Maintenance immunosuppressant therapy in these patients involves a calcineurin inhibitor (either cyclosporine or tacrolimus), and anti-proliferative agent (mycophenolate mofetil or one of its alternatives), and a short course of steroids

There was an active question-and-answer session regarding this very complex topic.

Continue page 18



DECEMBER 2023

SURGICAL GRAND ROUNDS, cont.

Hand Trauma: Practical General Principles

Dr. Mihaela-Elena Rapolti presented our Surgical Grand Rounds on “Hand Trauma: Practical General Principles” on 11/13/2023. She emphasized that during the second and tertiary survey of one who has been brought into the emergency Department for injury would include a thorough evaluation of the hands. The classic three imaging views (lateral, PA, and oblique) provide the basic views of the vast majority of injuries. She talked a bit about compartment syndrome which should be suspected when a patient does not have full function of the fingers or wrist, and this can be demonstrated to be present when there is a compartment pressure which exceeds 30 torr. Whenever a patient can fully extend the finger, one can be quite confident that there is no compartment syndrome.



Dr. David Edelman introducing speaker, Dr. Mihaela-Elena Rapolti

About 55% of level one trauma centers are able to replant severed fingers. The severed finger is traditionally put in a bag of ice in order to stop metabolism until the patient has replantation. One of the areas which is contraindication to replantation would be the finger that has been severed in “no man’s” land, which is the area between the distal palmar crease and the junction of the proximal end of the proximal phalanx. A number of patients will have displacement of fingers, and this can be reduced in the Emergency Department. One should get a good x-ray confirmation of reduction before putting on the splint and sending the patient for subsequent outpatient evaluation. The splinting of one finger is commonly done by securing it to the adjacent finger. Fractures can also be reduced in the Emergency Department with appropriate local anesthesia and post reduction radiographic confirmation of good position.

Most tendon and nerve injuries can be treated subsequently in the outpatient department. The skin can be closed primarily in the Emergency Department with the subsequent repair of tendons and nerves done later as an outpatient. She described that the finger block with Lidocaine plus epinephrine is safe and that the block should be done slowly and given over a period of many minutes, which will allow for a long-term anesthetic effect when the epinephrine has been added. If there is any concern about prolonged pallor of the finger following the Lidocaine with epinephrine injection, this can be easily reversed with a slow injection of phentolamine. She likewise indicated that the finger fractures can also be definitively repaired after being evaluated in about two weeks in the outpatient department.

Continue page 19

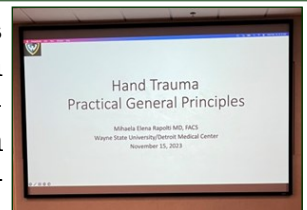


DECEMBER 2023

SURGICAL GRAND ROUNDS, cont.

Hand Trauma: Practical General Principles


Dr. Rapolti mentioned Dr. Kleinert and Dr. Kutz, who for many years ran the Hand Fellowship program in Kentucky. Dr. Kutz was born in Standish, Michigan whereas Dr. Kleinert grew up on a ranch in Sunburst, Montana after his father, Emil, moved there from Michigan in order to get work after he left Michigan with only a third grade education. The gray haired surgeons in the audience were taught by Dr. Joe Posch and Dr. Larsen, both of whom were friends of Dr. Kleinert and often had Dr. Kleinert present at Grand Rounds. Things have changed over the years; Dr. Posch, Dr. Larsen, and Dr. Kleinert recommended early operative intervention for penetrating hand wounds ideally occurring within the first 12 hours if there were no other injuries which precluded early hand intervention.



What I Learned at the ACS Meeting

The Surgical Grand Rounds for Wednesday, 11/29/2023, was provided by the senior level surgical residents who reported on their experiences from the October 2023 American College of Surgeons meeting; their presentations were titled, “What I Learned at the ACS Meeting.”

Dr. Felix Shun discussed the problems associated with distal colon obstruction due to cancer. He discussed how patients with extraperitoneal involvement may be treated for a high-grade obstruction by placement of a stent which can then be used as a bridge to get the patient prepared for operation, while the stent allows for the colon to decompress and be properly prepared for operation. He described the symptoms for both an upper rectal obstruction as opposed to a lower rectal obstruction. The patients with a mid to low rectal obstruction are more likely to have tenesmus and incontinence as opposed to the upper obstruction which presents with the upper rectal cancers which present with obstruction. He reported that the stent can yield a good result in about 90% of patients but that in some patients, it may migrate and be associated with injury to the colon. He



Dr. Felix Shun

Continue page 20

DECEMBER 2023

SURGICAL GRAND ROUNDS, cont.

What I Learned at the ACS Meeting

described how there are certain contraindications to the stent which include current therapy with anti-epithelial growth factor therapy since this can predispose to perforation. The type of stoma that is preferred should be that which is easy to perform with a more proximal stoma in the transverse colon, allowing for definitive surgery on the cancer to be performed without complications related to adhesions from a lower stoma. He also emphasized the importance of bringing the stoma through the rectus muscle and to be certain that there is good vascularity of the skin.

Dr. Puneet Bhatti discussed the ACS panel session dealing with compartment syndrome. He emphasized that the traditional measurement above which decompression is needed could represent an absolute intracompartment pressure of 30 torr or a measurement of 30 torr being the difference between the mean arterial pressure and the intracompartment pressure. He showed how a tibial fracture may lead to increased intracompartment pressure, but this seldom requires surgical decompression since the mean arterial pressure minus the intracompartment pressure seldom reaches 30. There are also ongoing studies on the utilization of ultrasonography in order to judge the intracompartmental pressure and thus far, this has a sensitivity rate of being accurate of about 80%. Whenever the intracompartmental pressure is not elevated, one can safely observe and simply take care of the fractures. He discussed how with fascial decompression, one can do a primary closure after the edema has subsided, or one can do a split-thickness skin graft when the open wound is quite large. He also described a “shoelace” closure where a continuous suture is placed and then gradually tied from one end to the other as the edema within the compartment subsides.



Dr. Puneet Bhatti

Dr. Anastasya Chuchulo discussed the ACS panel sessions that she attended regarding the difficult gallbladder. One of the panelists was Dr. Andrew Peitzman who emphasized the Critical View of Safety (CVS) and taking one’s time in order to do all of the dissection necessary to see the CVS. This is important to avoid common bile duct injury, particularly during laparoscopic cholecystectomy. This is a common problem, and anywhere from one-quarter to one-half of practicing surgeons have had at least one case of inappropriate common duct injury related to the difficult gallbladder. Whenever the inflammation is extensive and extends down beyond the end of the



Dr. Anastasya Chuchulo

Continue page 12


DECEMBER 2023

SURGICAL GRAND ROUNDS, cont.

What I Learned at the ACS Meeting

gallbladder to the common bile duct, the surgeon must go very slowly and utilize an intraoperative cholangiogram to help identify the anatomy. When the CVS cannot be properly identified, the options are to open, obtain cholangiography, ask for an experienced consult, do a cholecystostomy, or if one is to proceed with cholecystectomy, use the open approach. She also emphasized the importance of avoiding injury to the hepatic artery or portal vein when the inflammation is very extensive. The panel members also discussed cholecystectomy in the cirrhotic patient and emphasized that the early postoperative mortality is over 10% and that the 90-day mortality is above 90%. She emphasized that patients with severe ascites, mental compromised from the liver failure, and portal vein thrombosis are best treated with a low-fat diet while therapy is provided for the underlying liver disease. Although a TIPS procedure allowed the patient to have operation, a long-term mortality in this setting is dismal.

Dr. Jock Thacker discussed the treatment of esophageal cancer. He pointed out that sometimes the Ivor-Lewis procedure is performed through a posterior lateral thoracotomy. He also discussed the use of minimally invasive surgery for performing both the abdominal portion and the thoracic portion in patients requiring esophageal cancer for tumor. Nutrition is important, and he discussed how the J-tube may allow for feeding to take place during the adjuvant chemotherapy radiation therapy interval but that this may have some decrease in absorption. Many times the G-tube can be used on a long-term basis in preparation for operation. Utilizing robotic or minimally invasive techniques, several authors are reporting discontinuance of a nasogastric tube and chest tube within two days of surgery, followed by early feeding, and some even discharge patients home by the second day. More likely, patients who are operated on using minimally invasive techniques will be discharged home by five days. He pointed out that the more difficult operation, as evidenced by increased length of operation, is associated with an increased leak rate. Regarding the debate as to whether or not to get a swallow study prior to feeding, he reported that this is usually not very helpful. He discussed the role of pyloromyotomy and also Botox injection in order to allow for gastric emptying in view of the fact that there is denervation during the esophagectomy.



Dr. Jock Thacker

Dr. Alison Karadjoff discussed the approach to enterocutaneous fistulae. She emphasized that the first chore is to take care of the sepsis, then get the patient ready to tolerate a major operative procedure. Controlling the fistula output by various types of appliances

Continue page 22

DECEMBER 2023

SURGICAL GRAND ROUNDS, cont.

What I Learned at the ACS Meeting

is helpful in preparation for surgery, and it allows for the patient to have enteral feedings while surgery is being prepared. She pointed out that about 75% of these fistulae will close without operative intervention. This is especially true for those who have a drainage that is not excessive. Getting control of the fistula so that the patient can be active and participate in their recovery is important and increases the likelihood of non-operative closure. She also pointed out the value of utilizing the fistula drainage for nourishment by way of a feeding tube so that the patient does not lose all of the good things that are coming out through the fistula. Patients with Crohn's disease have a special problem with the development of enterocutaneous fistulae. With longstanding Crohn's, doing a fistulotomy rather than a bowel resection helps to preserve small bowel function. She also discussed the treatment of the perianal fistula in patients with Crohn's disease, emphasizing the role of the Seton. She suggested that the panelists would prefer to avoid mesh when operating upon patients with Crohn's disease, even though this may be associated with a high incidence of subsequent herniation.



Dr. Allison Karadjoff



ERRATUM

The Editor referred to Dr. Arthur Weaver in the November issue of the Monthly Email Report as a "Centurion" which is the leader of 100 Roman soldiers rather than a "Centenarian". The Editor will try to do better!



1/30/72 - Staff: Dr. John Kirkpatrick; Chief Resident: Dr. F. Irani

1. WD: SGW left leg, treated with debridement.
2. LS: Small bowel obstruction, treated with lysis of adhesions.
3. CJ: GSW right popliteal artery, treated with repair of artery and ligation of vein and debridement of wound.



Dr. Anna Ledgerwood

1/31/72 - Staff: Dr. William Harrity

1. LH: Stab left shoulder, left flank, and right upper quadrant. Abdominal tap positive for blood. Laparotomy showed lacerated spleen, treated with splenectomy. Patient had cirrhotic liver. Gastrostomy was also done.
2. PP: 23yo, SGW right forearm and right flank, treated with debridement of arm and drainage of liver injury.

2/1/72 - Staff: Dr. Zwi Steiger

1. TG: 20yo, GSW right lower chest, bullet at the level of L1 posteriorly. Had guarding in right upper quadrant; laparotomy showed no penetration of peritoneal cavity.
2. KM: Acute appendicitis treated with appendectomy.

2/2/72

Staff: Dr. Robert F. Wilson

1. CD: 33yo male, upper GI bleeding, treated with vagotomy and pyloroplasty for gastric erosions.
2. TG: Perforated peptic ulcer. Patient underwent laparotomy, gastrostomy, and tracheostomy.
3. KM: Acute appendicitis treated with appendectomy.

Continue page 24



"EXCERPTS FROM LOG BOOK" - DOWN MEMORY LANE, cont...

2/3/72 - Staff: Dr. R. Threlkeld

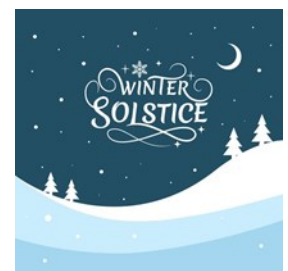1. BR: Hand abscess treated with drainage of thenar space abscess.
2. CS: 53yo patient in car crash with 12 right rib fractures and hemothorax with respiratory distress. Taken to O.R. for right chest tube and tracheostomy. BP dropped to 40 systolic, and 4 units whole blood given with no response. Exploratory laparotomy showed large fracture right and left lobe of liver with two liters of blood in abdomen. Laceration closed and bleeding under control. BP dropped, cardiac arrest, resuscitated, and patient expired in O.R.
3. GH: Stab left flank, negative laparotomy.
4. GR: 24yo with blunt trauma and fracture right nine ribs. Abdominal tenderness with rebound, lavage catheter was lost, exploratory laparotomy was negative.

2/4/72 - Staff: Dr. Pelok

1. BM: Stab right buttock and left thigh. Knife went thru-and-thru the anus, treated with closure of mucosa and drainage of the tract.

2/5/72 - Staff: Dr. Y. Silva; Chief Resident: Dr. Sankaran

1. LN: 31yo female, GSW abdomen with injury to small bowel requiring one resection and closure of two holes.
2. JS: GSW right thigh with femoral shaft fracture, treated with exploration of femoral vessels with no injury.
3. EA: Stab to left neck with hematoma, negative exploration of neck.





WSU MONTLY CONFERENCES 2023

Death & Complications Conference
Every Wednesday from 7-8



Didactic Lectures — 8 am
Kresge Auditorium

The weblink for the New WebEx Room:
<https://davidedelman.my.webex.com/meet/dedelman>

Wednesday, December 6

Death & Complications Conference

“ABSITE Quest Exam”

David Edelman, MD

Program Director, DMC/WSU Surgical Residency

Wednesday, December 13

Death & Complications Conference

Lawrence Diebel, MD

WSU Michael & Marian Ilitch Department of Surgery

Wednesday, December 20

Death & Complications Conference

“Home Alone! Resident Trauma Cases for the Holidays”

Andrew Isaacson, MD

WSU Michael & Marian Ilitch Department of Surgery

**RESGE AUDITORIUM – SECOND FLOOR WEBBER BLDG
HARPER UNIVERSITY HOSPITAL, 3990 JOHN R.
7:00 Conference: Approved for 1 Hour – Category 1 Credit
8:00 Conference: Approved for 1 Hour – Category 1 Credit
For further information call (313) 993-2745**

The Wayne State University School of Medicine is accredited by the Accreditation Council for Continuing Medical Education to provide continuing medical education for physicians. The Wayne State University School of Medicine designates this live activity for a maximum of 2 hours *AMA PRA Category 1 Credit(s)*[™]. Physicians should claim only the credit commensurate with the extent of their participation in the activity.”

EVALUATIONS

Surgical Death and Complications Rounds #2023321125, Sept-Dec 2023 CME Reflective Evaluation:

<https://www.surveymonkey.com/r/MF9YL7M>

Surgery Grand Rounds #2023321064, Sept-Dec 2023 CME Reflective Evaluation:

<https://www.surveymonkey.com/r/MNZD2V2>



**Wayne State Surgical Society
2023 Donation**

Name: _____

Address: _____

City/State/Zip: _____

Service Description	Amount
2021 Dues Payment _____ \$200	_____
My contribution for "An Operation A Year for WSU" _____	_____
*Charter Life Member _____ \$1000	_____
Total Paid _____	_____

Payment by Credit Card

Include your credit card information below and mail it or fax it to 313-993-7729.

Credit Card Number: _____

Type: MasterCard Visa Expiration Date: (MM/YY) _____ Code _____

Name as it appears on card: _____

Signature: _____

Billing address of card (if different from above):

Street Address _____

City _____ State _____ Zip Code _____

*I want to commit to becoming a charter life member with payment of \$1000 per year for the next ten (10) years.

Send check made payable to **Wayne State Surgical Society** to:

Charles Lucas, MD
Department of Surgery
Detroit Receiving Hospital, Room 2V
4201 St. Antoine Street
Detroit, Michigan 48201

MARK YOUR CALENDARS

*American Surgical Association 144th Annual Meeting
April 4-6, 2024
Grand Hyatt Hotel
Washington DC*

*Michigan Chapter of the American College of Surgeons
May 1-3, 2024
Radisson Plaza Hotel
Kalamazoo, Michigan*



*Please Update Your
Information*

The WSUSOM Department of Surgery wants to stay in touch. Please email Charles Lucas at clucas@med.wayne.edu to update your contact information.



Missing Emails

Over the years the WSU Department of Surgery has lost touch with many of its alumni. If you know the email, address, or phone number of the following WSU Department of Surgery Residency Program graduates please email us at clucas@med.wayne.edu with their information so that we can get them on the distribution list for the WSU Department of Surgery Alumni Monthly Email Report.

Mohammad Ali (1973)

David B. Allen (1992)

Tayful R. Ayalp (1979)

Juan C. Aletta (1982)

Kuan-Cheng Chen (1976)

Elizabeth Colaiuta (2001)

Fernando I. Colon (1991)

David Davis (1984)

Teoman Demir (1996)

Judy A. Emanuele (1997)

Lawrence J. Goldstein (1993)

Raghuram Gorti (2002)

Karin Haji (1973)

Morteza Hariri (1970)

Harrison, Vincent L. (2009)

Abdul A. Hassan (1971)

Rose L. Jumah (2006)

R. Kambhampati (2003)

Aftab Khan (1973)

Samuel D. Lyons (1988)

Dean R. Marson (1997)

Syed A. Mehmood (2007)

Toby Meltzer (1987)

Roberto Mendez (1997)

Mark D. Morasch (1998)

Daniel J. Olson (1993)

David Packer (1998)

Y. Park (1972)

Bhavik G. Patel (2004)

Ami Raafat (1998)

Kevin Radecki (2001)

Sudarshan R. Reddy (1984)

Renato G. Ruggiero (1994)

Parvid Sadjadi (1971)

Samson P. Samuel (1996)

Knavery D. Scaff (2003)

Steven C. Schueller (1974)

Anand G. Shah (2005)

Anil Shetty (2008)

Chanderdeep Singh (2002)

David G. Tse (1997)

Christopher N. Vashi (2007)

Larry A. Wolk (1984)

Peter Y. Wong (2002)

Shane Yamane (2005)

Chungie Yang (2005)

Hossein A. Yazdy (1970)

Lawrence S. Zachary (1985)

Wayne State Surgical Society

The Wayne State Surgical Society (WSSS) was established during the tenure of Dr. Alexander J. Walt as the Chairman of the Department of Surgery. WSSS was designed to create closer contact between the current faculty and residents with the former resident members in order to create a living family of all of the WSU Department of Surgery. The WSSS also supports department activities. Charter/Life Membership in the WSSS is attained by a donation of \$1,000 per year for ten years or \$10,000 prior to ten years. Annual membership is attained by a donation of \$200 per year. WSSS supports a visiting lecturer each fall and co-sponsors the annual reception of the department at the annual meeting of the American College of Surgeons. Dr. Scott Davidson (WSU/GS 1990/96) passed the baton of presidency to Dr. Larry Narkiewicz (WSU/GS 2004/09) at the WSSS gathering during the American College of Surgeons meeting in October 2022. Members of the WSSS are listed on the next page. Dr. Narkiewicz continues in the hope that all former residents will become lifetime members of the WSSS and participate in the annual sponsored lectureship and the annual reunion at the American College of Surgeons meeting.



Members of the Wayne State Surgical Society Charter Life Members

Ahn, Dean	Clink, Douglas	Gerrick Stanley	Lucas, Charles E.	Ramnauth, Subhash	vonBerg, Vollrad J. (Deceased)
Albaran, Renato G	Chmielewski, Gary W.	Grifka Thomas J. (Deceased 2022)	Malian, Michael S.	Rector, Frederick	Washington, Bruce C.
Allaben, Robert D. (Deceased)	Colon, Fernando I.	Gutowski, Tomasz D.	Marquez, JoFrances	Rose, Alexander	Walt, Alexander (Deceased)
Ames, Elliot L.	Conway, William Charles	Herman, Mark A.	Martin, Donald J., Jr.	Rosenberg, Jerry C.	Weaver, Donald
Amirikia, Kathryn C.	Davidson, Scott B.	Hinshaw, Keith A.	Maxwell, Nicholas	Sankaran, Surya	Whittle, Thomas J.
Anslow, Richard D.	Dente, Christopher	Holmes, Robert J.	McGuire, Timothy	Sarin, Susan	Williams, Mallory
Antonioli, Anita L.	Dujon, Jay	Huebl, Herbert C.	McIntosh, Bruce	Sferra, Joseph	Wills, Hale
Auer, George	Edelman, David A.	Johnson, Jeffrey R.	Missavage, Anne	Shapiro, Brian	Wilson, Robert F.
Babel, James B.	Engwall, Sandra	Johnson, Pamela D.	Montenegro, Carlos E.	Silbergleit, Allen	Wood, Michael H.
Bassett, Joseph (Deceased)	Francis, Wesley	Kline, Gary	Narkiewicz, Lawrence	Smith, Daniel	Zahriya, Karim
Baylor, Alfred	Flynn, Lisa M.	Kovalik, Simon G.	Nicholas, Jeffrey M.	Smith, Randall W.	
Bouwman, David	Fromm, Stefan H.	Lange, William (Deceased)	Novakovic, Rachel L.	Stassinopoulos, Jerry	
Bradley, Jennifer	Fromm, David G	Lau, David	Perrone, Erin	Sullivan, Daniel M.	
Busuito, Christina	Galpin, Peter A.	Ledgerwood, Anna M.	Porter, Donald	Sugawa, Choichi	
Crocco, William C.	Gayer, Christopher P.	Lim, John J.	Prendergast, Michael	Tuma, Martin	

Members of the Wayne State Surgical Society—2023-24 Dues

Alpendre, Cristiano V.	Goltz, Christopher J.	Marquez, JoFrances	Siegel, Thomas S.
Bambach, Gregory A.	Gutowski, Tomasz	Martin, Jonathon	Tarras, Samantha
Carlin, Arthur	Hall, Jeffrey	McGee, Jessica D.	Taylor, Michael G.
Chmielewski, Gary	Hollenbeck, Andrew	Mostafa, Gamal	Tennenberg, Steven
Dawson, Konrad L.	Joseph, Anthony	Nevonen, Marvin G.	Thoms, Norman W.
Dolman, Heather	Klein, Michael D.	Paley, Daniel S.	Vasquez, Julio
Dulchavsky, Scott A.	Kline, Gary	Park, David	Ziegler, Daniel W.
Fernandez-Gerena, Jose	Kosir, Mary Ann	Porterfield, Lee	
Field, Erin	Lloyd, Larry	Shanti, Christina	



Operation-A-Year January 1—December 31, 2024



The WSU department of Surgery has instituted a new group of alumni who are remembering their training by donating the proceeds of one operation a year to the department. Those who join this new effort will be recognized herein as annual contributors. We hope that all of you will remember the department by donating one operation, regardless of difficulty or reimbursement, to the department to help train your replacements. Please send you donation to the Wayne State Surgical Society in care of Dr. Charles E. Lucas at Detroit Receiving Hospital, 4201 St. Antoine Street (Room 2V), Detroit, MI, 48201.

Albaran, Renato G.	Dittinbir, Mark	Holmes, Robert J.	McGuire, Timothy	Sullivan, Daniel M.
Antonioli, Anita L.	Engwall, Sandra	Johnson, Jeffrey R.	McIntosh, Bruce	Wood, Michael H.
Bambach, Gregory A.	Fernandez-Gerena, Jose	Johnson, Pamela D.	Porter, Donald	Ziegler, Daniel
Bradley, Jennifer	Gutowski, Tomasz	Joseph, Anthony	Prendergast, Michael	
Busuito, Christina	Gayer, Christopher P.	Lim, John J.	Siegel, Thomas S.	
Chmielewski, Gary W.	Herman, Mark A.	Malian, Michael	Smith, Daniel	
Dente, Christopher	Hinshaw, Keith A.	Marquez, JoFrances	Smith, Randall	



WSU SOM ENDOWMENT

The Wayne State University School of Medicine provides an opportunity for alumni to create endowments in support of their institution and also support the WSSS. For example, if Dr. John Smith wished to create the “Dr. John Smith Endowment Fund”, he could donate \$25,000 to the WSU SOM and those funds would be left untouched but, by their present, help with attracting other donations. The interest at the rate of 4% per year (\$1000) could be directed to the WSSS on an annual basis to help the WSSS continue its commitment to improving the education of surgical residents. Anyone who desires to have this type of named endowment established with the interest of that endowment supporting the WSSS should contact Ms. Lori Robitaille at the WSU SOM> She can be reached by email at lrobitai@med.wayne.edu.